

Control & Therapy Series

Issue 305 | December 2021



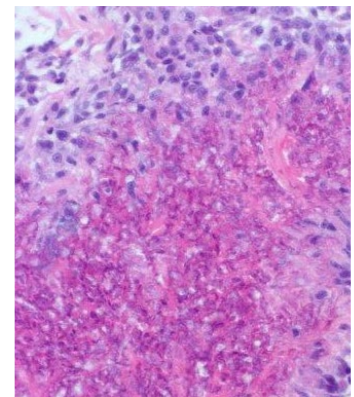
Management of Burns in Horses

44



Pure Breeding and Genetic Cruelty in
Australian Exhibition Budgerigars

18



Answer to 'What is Your
Diagnosis?'

33



Orphaned Mountain Lion Cub Successfully Treated for Burns Sustained in Deadly
California Wildfire

15

NexGard SPECTRA® *Let's go!*

The **most** complete parasite protection, all in one tasty chew

FLEAS
TICKS MITES
HEARTWORM
WORMS



Australia's leading parasite protection for dogs*

See product label for full claim details and directions for use.

*Based on sales data collected from Animal Medicines Australia (Baron) Audit Report – Canine Parasiticide Category – MAT June 2021.
Boehringer Ingelheim Animal Health Australia Pty. Ltd. Level 1, 78 Waterloo Road, North Ryde NSW 2113. ABN 53 071 187 285.

©NEXGARD SPECTRA is a registered trademark of the Boehringer Ingelheim Group. All rights reserved. PET-0041-2021

 **Boehringer
Ingelheim**

C&T

Issue 305 | December 2021

Control & Therapy Series

Australia's Leading Veterinarian Forum

PUBLISHER

Centre for Veterinary Education
Veterinary Science Conference Centre
Regimental Drive
The University of Sydney NSW 2006
+ 61 2 9351 7979
cve.publications@sydney.edu.au
cve.edu.au

Print Post Approval No. 10005007

DIRECTOR

Dr Simone Maher

EDITOR

Lis Churchward
cve.publications@sydney.edu.au

EDITORIAL ASSISTANT

Dr Jo Krockenberger
joanne.krockenberger@sydney.edu.au

VETERINARY EDITOR

Dr Richard Malik

DESIGNER

Samin Mirgheshmi

ADVERTISING

Lis Churchward
elizabeth.churchward@sydney.edu.au

DISCLAIMER

All content made available in the *Control & Therapy* (including articles and videos) may be used by readers (*You or Your*) for educational purposes only.

Knowledge and best practice in this field are constantly changing. As new research and experience broadens our knowledge, changes in practice, treatment and drug therapy may become necessary or appropriate. You are advised to check the most current information provided (1) on procedures featured or (2) by the manufacturer of each product to be administered, to verify the recommended dose or formula, the method and duration of administration, and contraindications.

To the extent permitted by law You acknowledge and agree that:

I. Except for any non-excludable obligations, We give no warranty (express or implied) or guarantee that the content is current, or fit for any use whatsoever. All such information, services and materials are provided 'as is' and 'as available' without warranty of any kind.

II. All conditions, warranties, guarantees, rights, remedies, liabilities or other terms that may be implied or conferred by statute, custom or the general law that impose any liability or obligation on the University (We) in relation to the educational services We provide to You are expressly excluded; and

III. We have no liability to You or anyone else (including in negligence) for any type of loss, however incurred, in connection with Your use or reliance on the content, including (without limitation) loss of profits, loss of revenue, loss of goodwill, loss of customers, loss of or damage to reputation, loss of capital, downtime costs, loss under or in relation to any other contract, loss of data, loss of use of data or any direct, indirect, economic, special or consequential loss, harm, damage, cost or expense (including legal fees).

Engage With Your Profession	2
From the Director	2
Sustainable Veterinary Careers-Survey	5

Small Animal

Suspected Eosinophilic Bronchopneumonia in a 1-Year-Old Jack Russell Terrier	Jonathon Nott	3	Winner
Dental-Mouth Anaesthetic Aid	John Sandford	6	Winner
Comments Courtesy of	Jacqui Norris & Pete Coleshaw ..	6	
Shining a Light on Laser Therapy	Aine Seavers	8	
Our K-Laser Experiences	Lynne Bodell	12	
Laser Therapy	Ray Ferguson	14	
Mitotane—Is Australia About to Lose This Essential Drug?	Sue Foster	24	
To Bleed or Not to Bleed?—That is Still the Question in 2021	Aine Seavers	25	
Submandibular Swelling Post Methimazole Treatment	Christopher Simpson	31	
Feline Lungworm (<i>Aelurostrongylus abstrusus</i>) Infection in a Kitten	Ben Mills	38	Winner
In-house Baermann Test	Jan Slapeta	40	
Another Variation of the In-House Baermann Test Courtesy of	Liz Smit	41	
The Unforeseen Animal Welfare Impacts Associated with Bushfires	Andrea Harvey	42	

General

Orphaned Mountain Lion Cub Successfully Treated for Burns Sustained in Deadly California Wildfire

Cover image courtesy of fox40.com

Stephanie McEwan	15	Winner - Best Visuals
-------------------------------	----	-----------------------

Replies

Answer to 'What is Your Diagnosis?' C&T No. 5898		
Sublingual Lesion in a Cat	Hannah Wilson & Randolph Baral	33
And a Similar Answer	Pete Coleshaw	36

Avian

Pure Breeding & Genetic Cruelty in Australian Exhibition Budgerigars	Don Burke	18
--	------------------------	----

Perspective

Specialists' Corner	Edwina Wilkes	43	
Management of Burns in Horses	Edwina Wilkes	44	Major Winner

Season's Greetings!

CVE Close Down

Our last day is Thursday 23rd December, reopening on Monday 10th January.

(Image courtesy of Anne Quain. Photography by ShootVaPooch)



ENGAGE WITH YOUR PROFESSION

Established in 1969, this unique veterinary publication celebrates over 50 years of veterinary altruism. An ever-evolving forum gives a 'voice' to the profession and everyone interested in animal welfare. You don't have to be a CVE Member to contribute an article to the C&T Series. Send your submissions to Dr Jo Krockenberger:

joanne.krockenberger@sydney.edu.au

"I enjoy reading the C&T more than any other veterinary publication."

Terry King

Veterinary Specialist Services, QLD

Thank you to all contributors

The C&T Series thrives due to your generosity. If you're reading this and have been contemplating sending us an article, a reply or comment on a previous C&T, or would like to send us a 'What's YOUR Diagnosis?' image and question or seek feedback from colleagues, please don't hesitate to contact us.

The C&T is not a peer reviewed journal. We are keen on publishing short pithy practical articles (a simple paragraph is fine) that our readers can immediately relate to and utilise. And the English and grammar do not have to be perfect—our editors will assist with that.

Join in—write up that interesting case

C&T authors agree that it is extremely satisfying to read their articles in print (and digital versions) and know they are contributing to veterinary knowledge and animal welfare.

Winners

Major Winner

Prize: A CVE\$400 Voucher

Management of Burns in Horses Edwina Wilkes44

Best Visuals

Prize: Digital video or DVD of your choice. Visit cve.edu.au/cveshop to peruse our list of titles.

Orphaned Mountain Lion Cub Successfully Treated for Burns Sustained in Deadly California Wildfire

Stephanie McEwan15

Winners

Prize: A CVE\$100 voucher

Suspected Eosinophilic Bronchopneumonia in a 1-Year-Old Jack Russell Terrier Jonathon Nott3

Dental-Mouth Anaesthetic Aid John Sandford.....6

Feline Lungworm (*Aelurostrongylus abstrusus*) Infection in a Kitten Ben Mills.....38

FROM THE DIRECTOR



Last week small animal surgeon Philip Moses was my guest in our WebinarLIVE! series. For those of you that don't know Philip, his particular area of expertise is surgical correction of conformational issues in brachycephalic breeds. He is also very outspoken about the welfare implications of breeding for phenotypes that impact the wellbeing of these dogs, and the need to revise breed standards accordingly. Don Burke writes of a similar concern in the breeding of budgerigars on page 18. It really does make me think of the wide spectrum of considerations encompassed in the term 'welfare', and the role we play, as veterinarians, to interpret and communicate these.

One of the most remarkable stories of the year features in this edition of the C&T—Edwina Wilke's recount of caring for severely burnt horses post the 2019/20 bushfire crises is one of perseverance and hope. The accompanying images are remarkable. Likewise some of the photographs within Stephanie McEwan's report of treating mountain lion cubs for burns following the Californian wildfire.

As ever, this edition abounds with practical tips to aid you in clinical practice: from in-house Baermann tests, to a novel aid for dentistry and a summary of vitamin K treatments which is sure to become your cut-out-and-keep guide.

Despite all this content, it's a small detail that really caught my eye and has stayed with me long after reading Hannah Wilson and Randolph Baral's response to 'What's Your Diagnosis?' has changed my management considerations of the pruritic cat. But more than that, I doubt I'll ever look at my Weetbix the same way again. I wonder if you'll feel the same—check out the text box on page 35.

Take care, happy reading—and wishing you contentment for 2022.

Simone

Small

SUSPECTED EOSINOPHILIC BRONCHOPNEUMONIA IN A 1-YEAR-OLD JACK RUSSELL TERRIER

Jonathon Nott

Brunker Road Vet Centre

278 Brunker Rd, Adamstown NSW 2289

nottj@hotmail.com

C&T No. 5903

Maggie, a 12-month-old, female Jack Russell Terrier, presented with an acute onset of a productive cough, gagging and retching for 24 hours.

The dog appeared bright, alert, responsive, and no other abnormalities were described by the owners. She was fully vaccinated, ate a regular commercial dog food diet, and was on monthly parasite control for fleas, tick, heartworm, and intestinal worms.

Two weeks prior to developing respiratory signs she had a low-grade, intermittent diarrhoea that had resolved. On examination there was tracheal hypersensitivity, and a harsh productive cough was noted. Vitals were otherwise normal, and she was prescribed a course of doxycycline (5mg/kg BID).

A week later, Maggie re-presented with signs of dyspnoea, a progressive productive cough, weight loss, lethargy and inappetence. Examination at this time revealed a moderate inspiratory and expiratory dyspnoea with mild tachypnoea, a heart rate of 120bpm, no audible murmur, mucous membranes were mildly cyanotic, however SPO₂ was 93%. Rectal temperature was 38.3°C and femoral pulse quality was good. Radiographs taken at this time revealed a diffuse, patchy bronchioalveolar lung pattern. Full haematology and biochemistry were unremarkable apart from a mild leukocytosis due to a lymphocytosis [5.3 (1.0–3.6)] and a marked eosinophilia [12.2 (0.1–1.2)].

Maggie continued to deteriorate and further investigation including a thoracic CT, bronchoscopy and bronchoalveolar lavage was undertaken. CT confirmed a diffuse/patchy moderate to severe bronchioalveolar pattern with some bullae/cyst

formation and bronchiectasis. Pleural thickening and mild mediastinal lymph node enlargement were also noted. Bronchoscopy allowed visualisation of diffuse, oedematous bronchial mucosa with moderate mucopurulent discharge within the mainstem bronchi. BAL cytology revealed a mixed neutrophilic (75%; normal <5) and eosinophilic (22%; normal <5) inflammatory pattern. The eosinophilia was suspected to be the instigating cause and the neutrophilia secondary. A positive *E. Coli* growth was obtained, and no parasitic larvae were found. LCAT, heartworm and faecal floatation tests were all normal.

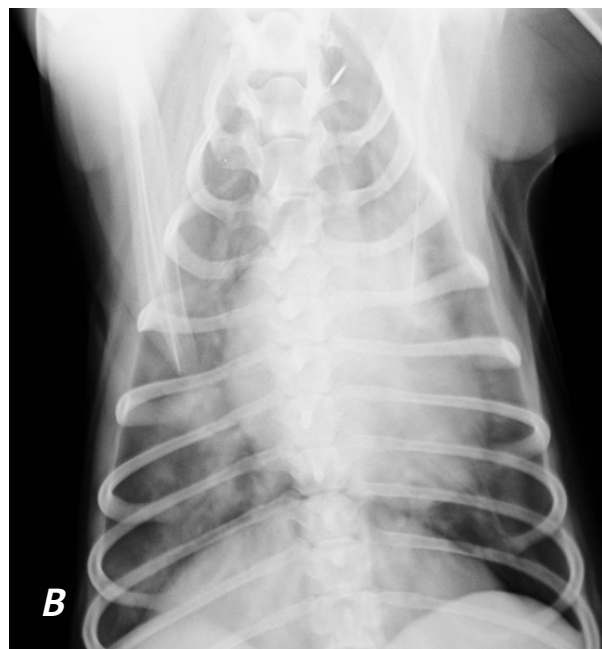
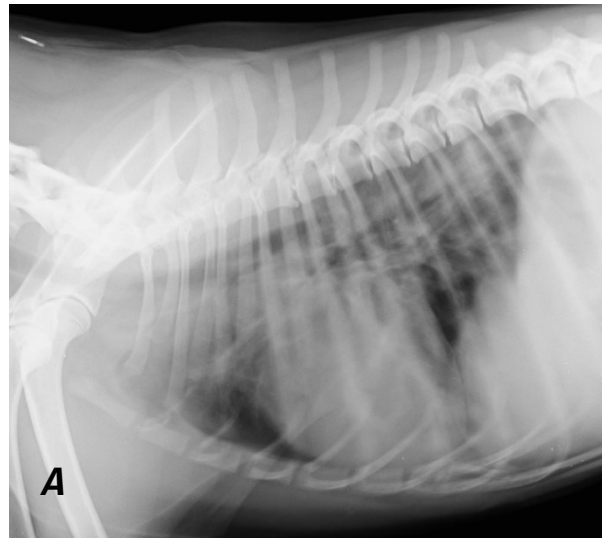


Figure 1. Lateral and dorsoventral thoracic radiographs of a 1-year-old JRT prior to treatment. Note the spectacular alveolar disease!

Maggie was initially treated with 14 days fenbendazole (50mg/kg) and enrofloxacin (5mg/kg SID). After 7 days with no improvement the antibiotics were switched to trimethoprim

sulphonamide (15mg/kg BID) as Pneumocystosis was considered a potential differential. After a further 7 days with no clinical improvement Maggie was started on prednisolone (1mg/kg sid).

Within 7 days of starting prednisolone, Maggie had markedly improved and clinical signs had almost completely resolved within four weeks. The trimethoprim sulphonamide was discontinued after 3 weeks. Follow up radiographs taken at four weeks showed marked improvement of the bronchoalveolar pattern. A fungal culture from the BAL grew *Trichosporon asahii* three weeks after submission and was suspected to be a contaminant.

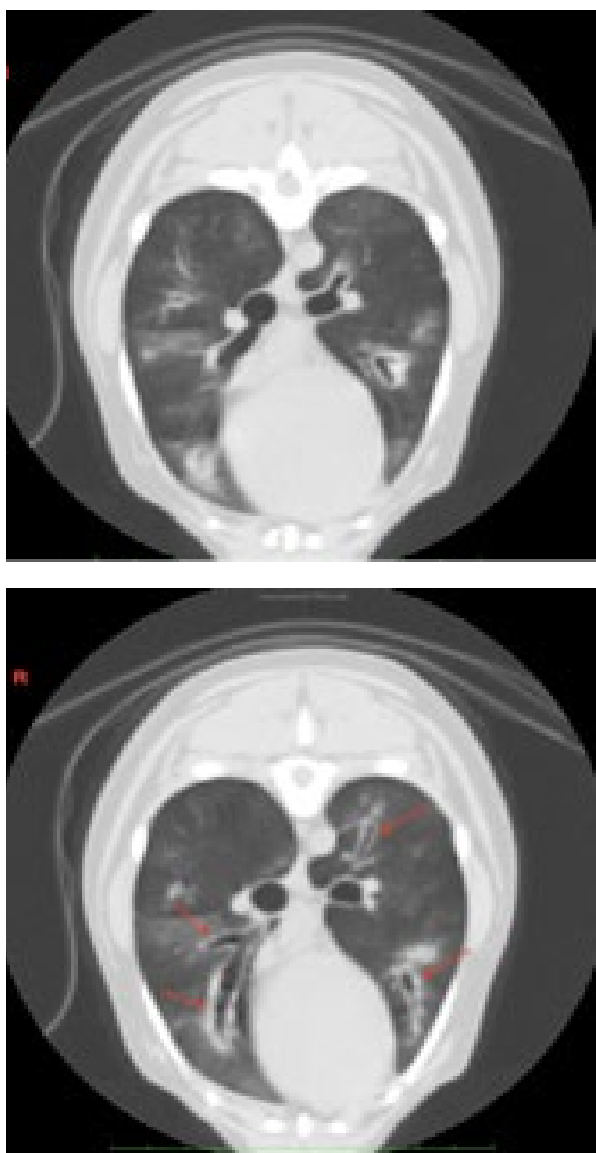


Figure 2. Two axial CT images of the thorax with bronchoalveolar pattern and bronchiectasis (red arrows).

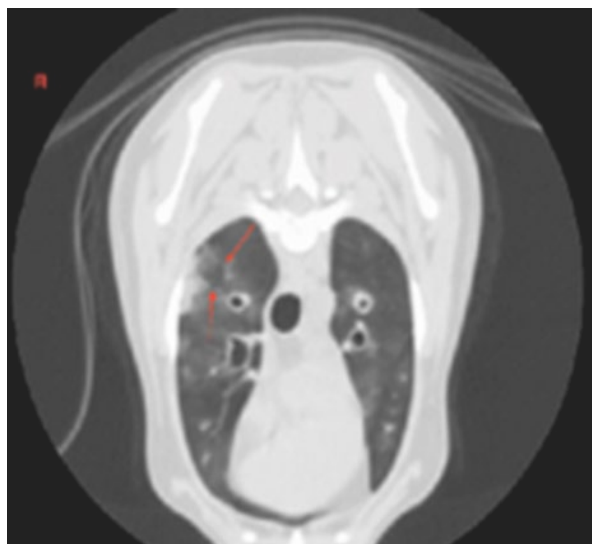


Figure 3. Axial CT images at the level of the right cranial lung lobe. Suspect formation of bulla/cyst/abscess (red arrows)

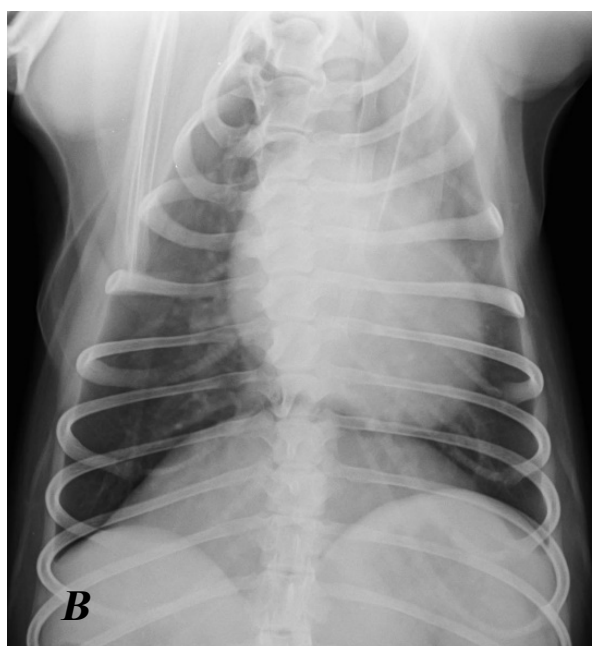
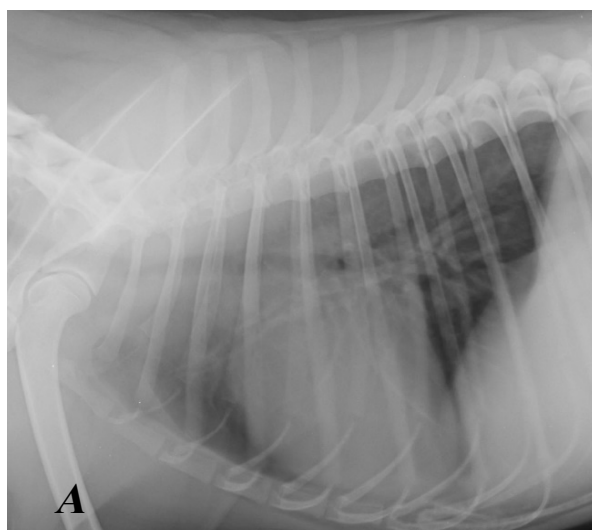


Figure 4. Lateral (A) and dorsoventral (B) thoracic radiographs of a 1-year-old JRT after 4 weeks of treatment with prednisolone. Note the huge improvement in the lung field radiographic appearance!

After the follow up radiographs, azathioprine (2mg/kg SID initially then EOD after 6 weeks) was instigated and the prednisolone was slowly tapered off over 8 weeks.

Given the response to prednisolone and the lack of response to all other medications, a suspected diagnosis of *eosinophilic bronchopneumonia* was made. To achieve a more complete diagnosis a lung lobe biopsy would likely need to be performed. The lasting and significant response to prednisolone suggested the positive fungal culture was a contaminant. However, as well as lung lobe biopsy, further confirmation may have been achieved by running a serum galactomannan assay.

Discussion of Eosinophilic Bronchopneumonia

Eosinophilic bronchopneumonia is considered to be a hypersensitivity reaction and is characterised by eosinophilic infiltration of alveolar and bronchial mucosa. Suspected and known causes of pulmonary hypersensitivities in humans and animals include fungi, moulds, drugs, bacteria, and parasites. Eosinophilic bronchopneumonia can be associated with heartworm infection and *Angiostrongylus vasorum* (lungworm) in dogs. However, in many cases, no underlying cause is found.

Affected dogs are usually young adults with a breed predisposition (huskies and malamutes), but the disease can be diagnosed in other large and smaller breeds (such as Jack Russell Terriers, Dachshunds) less commonly. The main clinical signs include coughing, gagging, retching and dyspnoea.

The most common radiographic findings are a mixed moderate to severe bronchointerstitial pattern. Computed tomographic findings include bronchial wall thickening, bronchiectasis, presence of pulmonary nodules, and lymphadenopathy. Peripheral blood eosinophilia is frequently, but not always observed. BAL cytology demonstrates a marked eosinophilic component and eosinophilic infiltration of the bronchial mucosa can also be observed in lung lobe biopsies. Concurrent neutrophilic inflammation can also be seen. Definitive diagnosis often rests on exclusion of other respiratory diseases.

The response to oral steroid therapy is generally excellent, although total resolution of symptoms is not always obtained. Relapse frequently occurs within weeks to months after drug discontinuation often requiring long term (even lifelong) treatment. Hence the addition of a secondary immunosuppressive drug in this case. Appropriate anthelmintic drugs can be used to treat potential parasites.

I would like to acknowledge **Gail Melliush** (Cameron Park Veterinary Clinic) as the primary care veterinarian and for providing the attached radiographs, **Karon Hoffman** and **Renée Léveillé** for providing specialist CT interpretation and the attached CT images. And **Richard Malik** for his general advice on this case. ♦



What if you could shape the future of veterinary work cultures?

There's a lot of talk about what contributes to the perceived shortage of vets and nurses, and dissatisfaction in the veterinary profession. Meanwhile, social scientists know a lot about what motivates and satisfies people in work and life contexts. What if we could link the two?

A new, independent Not For Profit organisation is under development to do just that. The team behind Sustainable Veterinary Careers sustainableveterinarycareers.org/ is asking everyone – at every career stage in every role within the animal health industry, including those who've moved on to other sectors – to tell us what you need and want to make the difference between surviving and thriving in vet. Would you support the proposed funding model, and how do you think funds should be governed and used?

Survey participation is completely voluntary and anonymous. The results of this ethics-approved survey (Deakin University approval number BL-EC 29 21) will be available to the entire industry. You'll be able to use the information in your own contexts as well as contribute to a pan-professional solution.

Veterinary professionals – students, managers, teachers, customer care and nursing staff and veterinarians are warmly invited to click on bit.ly/SVC-survey to tell us what your veterinary future should include.

Winner

Entitled to a CVE\$100 voucher

Small

DENTAL-MOUTH ANAESTHETIC AID

John Sandford BVSc

Clifton Hill Vet Clinic

470 Wellington St, Clifton Hill VIC 3068

+61 39489 4055

jandk@jsandford.com.au

C&T No. 5904

I am prompted to write this article by noticing that in all the veterinary procedures that I have seen on TV, read in text books or vet sales publications etc. over the years, none have demonstrated anything similar to what I utilise and their methods need more staff assistance, make things more difficult, and have higher risk of injury.

I don't know when I first thought of using the red rubber stoppers (Figure 1), but I have been using them for the last 50 plus years. Recent enquiries have led me to be surprised that nothing like these practical rubber stoppers have wide spread use in veterinary clinics. I use them for ANY head procedure in a cat or dog involving intubation for an anaesthetic (no other person or instrument needed), any mouth/throat surgery, or as the most common need, to keep the jaws separated for virtually any dental work. Rather than using the common spring-loaded metal retractors keeping the canines apart, the plugs are out of the way 99% of the time.

They are preferably placed posterior to the last molars (see Figure 2) or, if literally all have been removed, a larger one can be placed between the canines (or use the metal retractors).

I always choose ones that give a pretty tight fit and have NEVER had any post use problems.

Post use, I just scrub clean them, soak in iodine surgical scrub for half an hour, rinse and dry. I have never autoclaved them—the mouth is surely an absolute bacterial rubbish tip anyhow. When the animal is becoming light out of the anaesthetic, they start slightly chewing the stopper, and that's a really good indication to promptly remove the endotracheal tube and still have a short moment to check the mouth etc. I would be lost without them. Use them once and you'll never not use them again. These stoppers were originally made for the chemical laboratory industry etc. I have 12 sizes

from 10mm to 70mm. Can I suggest that any locums or assistants reading this – show it to the boss.

My motto – use the KISS system!

These stoppers are available from APSCAN Pty. Ltd.
– Veterinary Supplies and Instruments.

COMMENTS COURTESY OF

Jacqui Norris

Professor of Veterinary Microbiology & Infectious Diseases, University of Sydney

Scrubbing clean and soaking in iodine kills most things including Feline Calicivirus (FCV).

Chlorhex doesn't kill FCV. Alcohol will not penetrate the cracks in rubber well.

Disposing of them frequently is advisable as the more worn the rubber becomes, the more cracked it becomes and harder to clean and disinfect.

Pete Coleshaw

Jaffa's Health Centre for Cats
Salisbury, United Kingdom

jaffa@jaffavets.com

Where have you been all of my life?

I used the spring gags from day one of my career until I learned of over-stretch injuries. Apart from this risk, I found them to be a nuisance when we moved to surgical extractions, as suture materials always seem to gravitate to the metalwork.

For my cats, I then retreated to 'sawn-off' needle shields inserted into the tips of the canines (when present), but so often these get displaced.

Now I use nothing other than my throat pack and digital manipulation of the jaw to facilitate exposure—most of the time. Occasionally I get my nurse to hold the jaw open, or stuff a moistened swab into the angle of the opposing jaw in the manner of these rubbers. So I like this idea—obviously no good if the rear cheek teeth have gone AWOL, but for those that have them it looks good to me and I will be looking to try to source. ♦



Editor's note – remember to take care when using any mouth gags to avoid over-stretching the jaw, particularly in cats where excessive tension can decrease arterial blood flow to the eye and brain. See eBook for references.

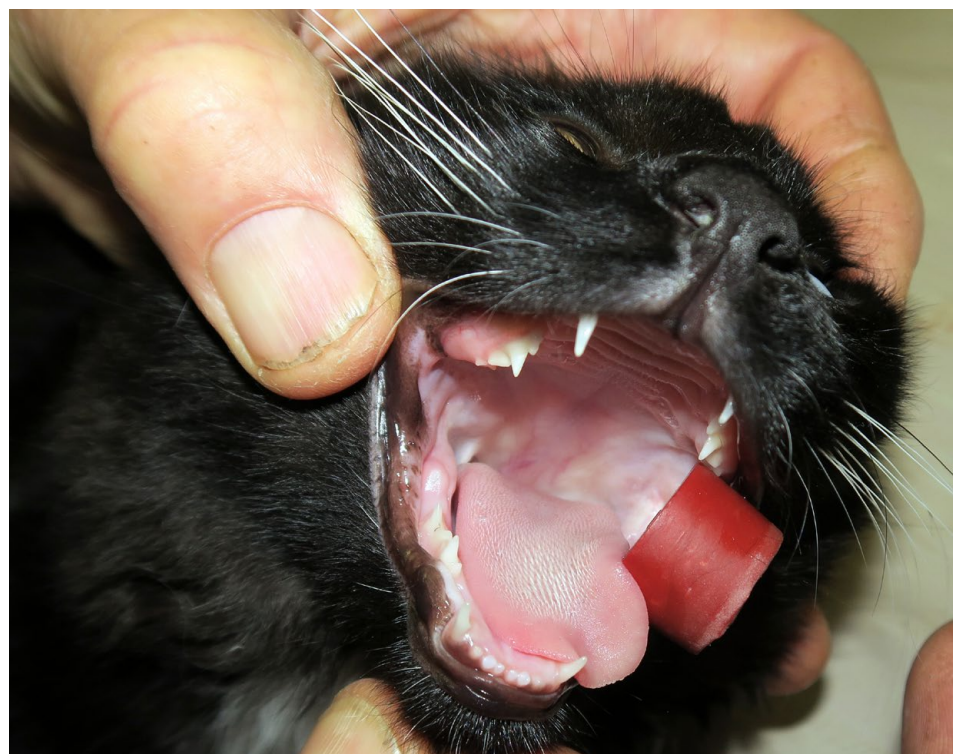
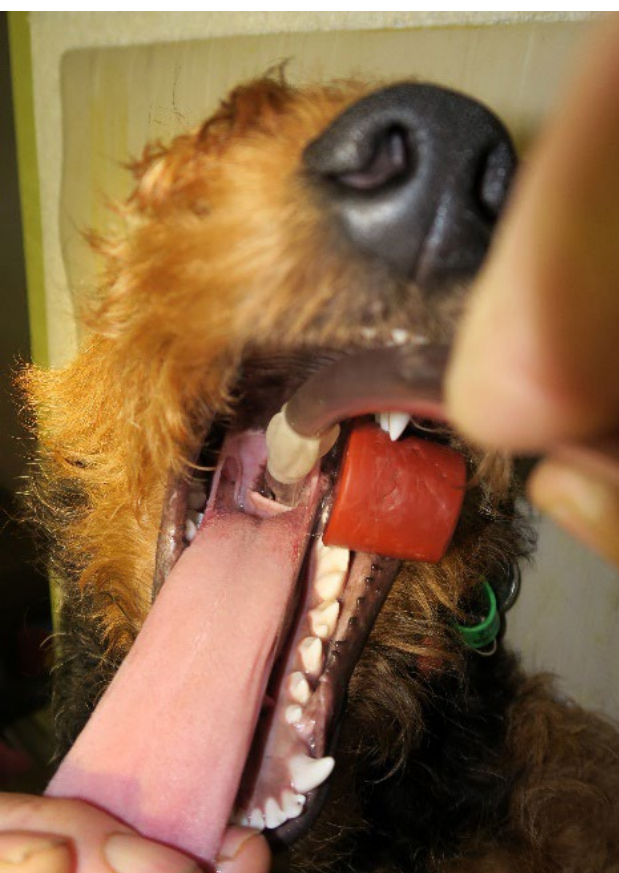
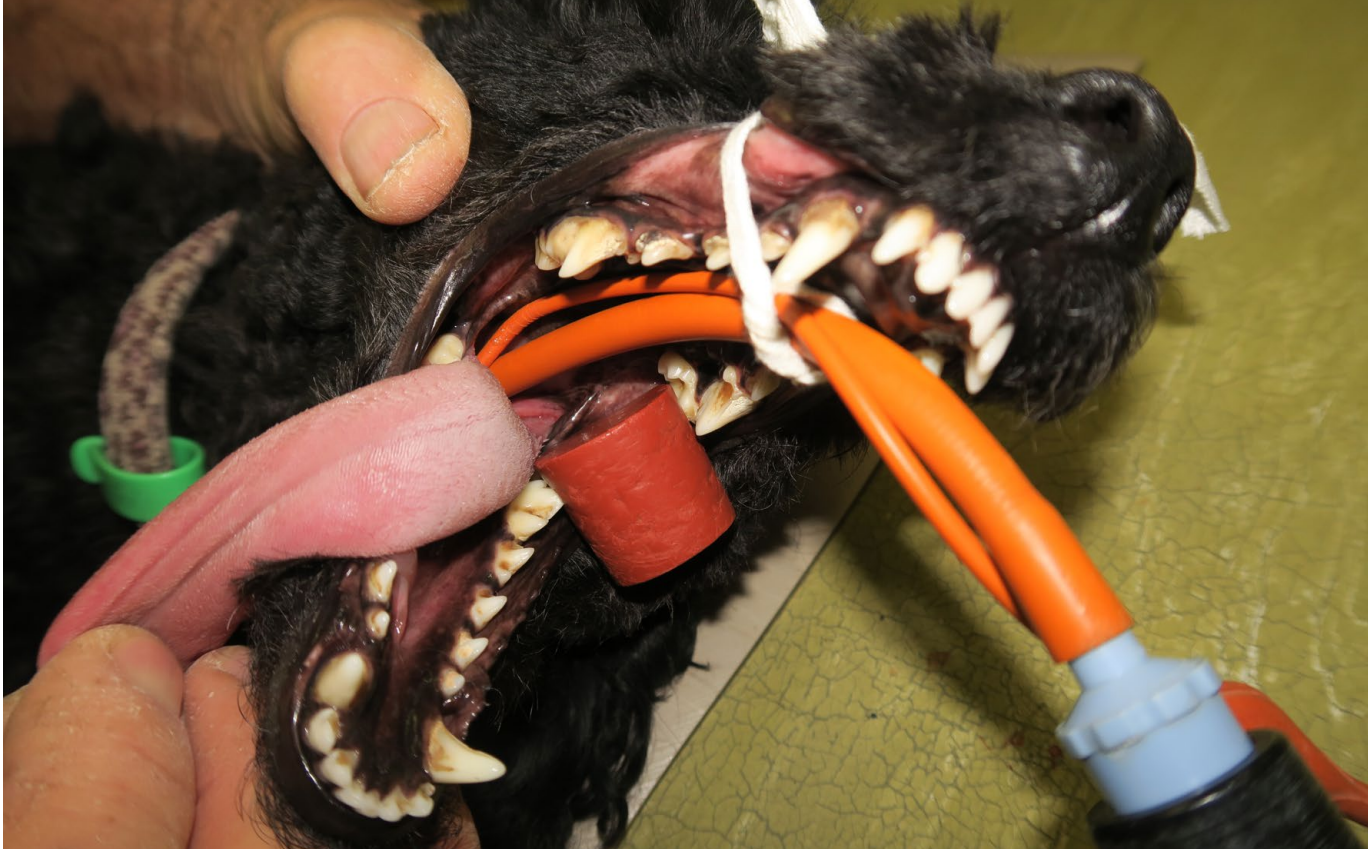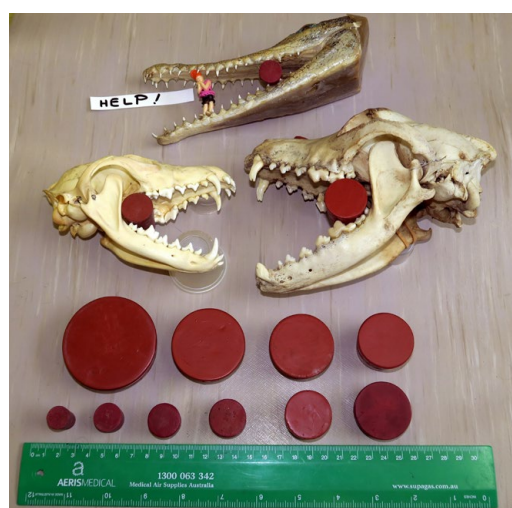Figure 1. Red rubber stopper in situ holding the jaws open for a dog dental

Figure 2. Me about to intubate without ANY assistance at all

Figure 3. Red rubber stopper in situ holding the jaws open for a cat dental

Figure 4. Range of red rubber stoppers (Featured on the cover)



Small

SHINING A LIGHT ON LASER THERAPY

Dr Aine Seavers

Oak Flats Vet Clinic

58A Central Avenue Oak Flats NSW 2529

vets@oakflatsvet.com.au

C&T No. 5905



If you have an apple and I have an apple and we exchange these apples then you and I will still each have one apple.

But if you have an idea and I have an idea and we exchange these ideas, then each of us will have two ideas.'

For all my veterinary life, I have been driven by the above concept.

Good knowledge shared is a great source of joy and healing and really does reduce the risk of burnout.

Following an incident on a recent winter holiday, I decided it was time to share my knowledge and personal tips about 'Laser'/Photobiomodulation therapy (PBMT) with C&T readers.

First; The What and The How of PBMT

PBMT is a NON-THERMAL therapy, using focussed light, usually in the non-visible light range (700nm-1100nm).

The focussed light acts upon chromophores primarily in the mitochondria to elicit photophysical and photochemical events. This process results in beneficial therapeutic outcomes including but not limited to: the alleviation of pain, immunomodulation, and promotion of wound healing and tissue regeneration.

The primary target of the PBMT is the Cytochrome C complex. This in turn results in:

- Increased production of ATP specifically in injured cells and helps to restore normal cellular function
- Production of free nitric oxide (NO) and modulation of reactive oxygen species (ROS) resulting in decreased inflammation.
- For PBMT to occur, light needs to reach the mitochondria of the damaged target tissue. When laser therapy is applied to the surface of the skin, the best results are achieved when a sufficient amount of light (number of photons) reaches the target tissue.

Treatment plans are based on JOULES per sq. cm (i.e. dosage).

The term PBMT is now more commonly used than the terms-low level laser therapy (LLLT) or Cold Laser Therapy. The advent of the more powerful Class 4 Laser machines, which do in fact create some heat, render the older terminology inaccurate. However this heat is not a problem when the device is used correctly.

Not only has this technology overcome my widely known, often feared, ingrained scepticism of anything new until it has passed significant scrutiny and research on my part, this laser technology has instead completely captivated my thought processes.

Suddenly PBMT therapy became more than just dealing with joint and orthopaedic or rehabilitation cases-for me, it has opened up a whole new in-consult world of soft tissue, wound management and skin disease therapy alternatives.

The high powered 30W-Class 4, the compact, light and highly portable Vets1Laser machine we selected, became the game changer in our daily work. Additionally, within 12 months of its initial purchase and without really trying, we more than cleared its \$18,900 purchase price.(Fig.1). <https://Vets1Laser.com/>).

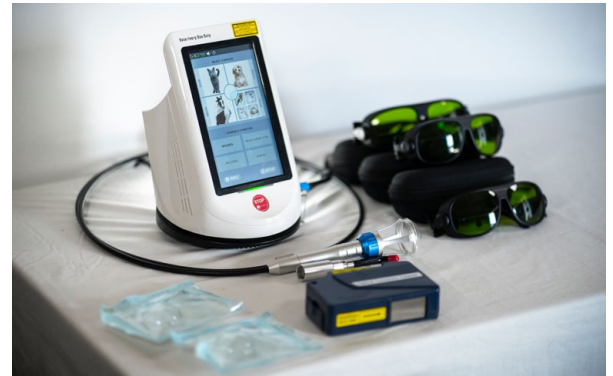

Figure 1. Vets1Laser

Inter/Intra Class Machine Variation

Our initial research highlighted that we need to focus on the Class 4 laser series. Interestingly, even within the same class, we found a huge difference in the power/time treatment equation offered by any given Class 4 machine and also a significant purchase price differential.

As anything >0.5W is classified as a Class 4 machine, a higher constant Power output is far more important than just being a Class 4 Laser. Otherwise, depending on your machine, you could end up taking 26 minutes rather than 3 minutes to treat a given problem. That longer treatment duration represents an expensive error in regards to allocation of time, money and resources.

After much discussion and more research, we selected a particular Class 4 machine that offered the same higher power, lower time cycles as the \$30,000-\$35,000 Class 4 machines, but at a much lower and affordable entry price.

The savings we made on the purchase price quickly went back into to buying a second laser to cover the increased demand for the therapy.

However, the real payoff was in the reduced stress to clients and to vets and in the increased joy in pets and Vets. No other technology has ever made us hear or share the funny, heart-warming, joyous stories that our new machine generated. We mopped up many chronic malingering cases, dramatically dropped the pain levels of so many pets and increased their quality of life. The Nurses were happier, the Vets less stressed and the Clients total converts: for what they perceived as great results and value for money.

This experience, of implementing new solutions and approaches for old problems is classic 'Tom's Paddock' stuff so, it should have been a no-brainer that I would share my findings with *C&T* readers.

Except; in so sharing, I would, for the first time in 15 years of writing for *C&T*, possibly financially benefit from such a submission as I now had a major conflict of interest.

So impressed was I by the technology, that our family Tech. Business commenced selling this Class 4 Vets1Laser machine.

As a result, I felt too conflicted to write for *C&T*, right up until an incident on holidays in May this year. The incident below, convinced me I was pre-judging my vet colleagues unfairly and in so doing, denying vets and pets the ability to have a lot better quality of life.

The 'Why' or The 'Back-Story': In more ways than one

The incident which triggered me to write this article was being invited by friendly locals from the town where we were holidaying, to join them for evening cocktails at their home.

At that lovely event, in the home of then strangers, now friends, their 48kg (people-aggressive) rescue dog suddenly started to emit high pitch screams suggestive of cervical and lumbosacral neuromuscular pain. Fun...Not!

Late in the evening and remote from a vet clinic, the medico owners were urged to keep the dog confined and to organise to see their own vet as soon as possible. By early morning, it was almost

impossible to get this dog safely (for both dog and humans) into their truck to transport to a vet clinic. By happenstance, our laser machine was in our car boot for use on my own IVDD.

(Disclaimer—whilst the Vets1Laser has a full complement of human setting and programs—which allow me to utilise it for my own personal use—this machine is sold solely for veterinary commercial use. Despite the many requests, we get from owners asking if they can also be treated—we politely decline to avoid a possible quagmire of legal and liability concerns).

Within 2 hours of just one laser session on the dog's affected areas, this dog was then able to be safely transported to town for imaging; and apparently to self-negotiate the set of steep stairs at that clinic! Their vet dispensed pain medication, a grave prognosis and referral to a specialist service—the latter some significant distance away. The owners were in shock.

The next morning, we ran another laser on the dog's lower back and neck before we had to head off home. This dog, with every excuse to be aggressive from the pain, was instead super-responsive to my partner in a way we have seen with these laser cases—the animals very quickly associate the device/person with feeling better. That evening, we received an emotional text from the owners with major thanks for our help. Their pet had improved remarkably that day, and was now transportable to a specialist if needs be,

After that emotional, grateful text, I decided to get over my inner conflict and spread the word, so that other Vets can bring such positivity into their workday. So here goes:

My personal findings and feedback on PBMT/Laser technology

As a general Clinician, I can't think of a single other tool or instrument or technology that helps me across so many clinical presentations as does our Laser therapy machine.

Whilst most vets would automatically reach for the laser in orthopaedic or rehab issues or for the surgical applications of the machine, the quirkier clinical applications we use it for most days include:

- Quick adjunct in-consult treatment for Otitis; both external and internal.
- Used as an adjunct therapy to those multi-drug resistant otitis or skin lesions, additional laser therapy has been without par in the fight to help rebalance the microbiome of those areas.

- Dramatic improvement in those pesky bleeding pinnal lesions and distal limb ulcers/wounds,
- Anal sacculitis adjunct treatment; helps with reducing pain and impaction. Helped accelerate healing of some of the more recalcitrant infections non-responsive to diet, weight control, antibiotics, sac flushing, pain control, dietary supplements etc. These mostly small breeds, with their weak or small anal sphincter muscles overwhelmed at any time, but especially when having to deal with hardened infected contents, seem to really benefit from the laser: The latest case is a Pug with life-long anal sac issues, who, once the laser was added into his therapy regime, obtained an 18-month disease free interval.
- Bladder pain
- Non-healing or severe trauma wounds
- Those horrendous inflamed infected dog-fight wounds; drains dripping everywhere, sites so swollen and painful the animal can't rest or lie properly—running the Class 4 machine results in an improvement so rapid that it can only be described 'scientifically' as simply 'Miraculous'.
- Pug Rhinitis
- Small warts, skin tags/cysts.
- Cautery—using special cutting adaptor
- Dental lesions
- Orthopaedic/Rehabilitation. As anyone who uses a powerful laser knows, when it comes to Ortho/Rehab cases, laser technology is in a treatment class of its own; often removing the need for additional physiotherapy or hydrotherapy.

Indeed, it was this first cohort of musculoskeletal cases who drove the scepticism from my eyes and made me a believer.

Dogs, who traditionally hated vet clinics, would suddenly come crashing through the front door, owner pulled almost airborne as their dogs bypassed the consult room and determinedly headed straight for the laser machine area.

Dogs screaming in the clinic car park no longer meant a cervical disc was about to blow; rather that Rosie or Charli were obviously on their way in for their laser session, whereupon they sit angelic-like as they have their treatment session.

One poodle is so smart, he readjusts himself to give the vet better access to his painful joints.

Consider the once aggressive Rottie, who brings her own bed and now lies unmuzzled, as she has the oedema on her hind leg successfully reduced with intermittent laser sessions. (Fig.2)

No one has failed to smile at the story of Bruce, the young 70kg mastiff, so habituated to his many oral meds and supplements that he slept all day to address the remaining unresolved pain, who awoke

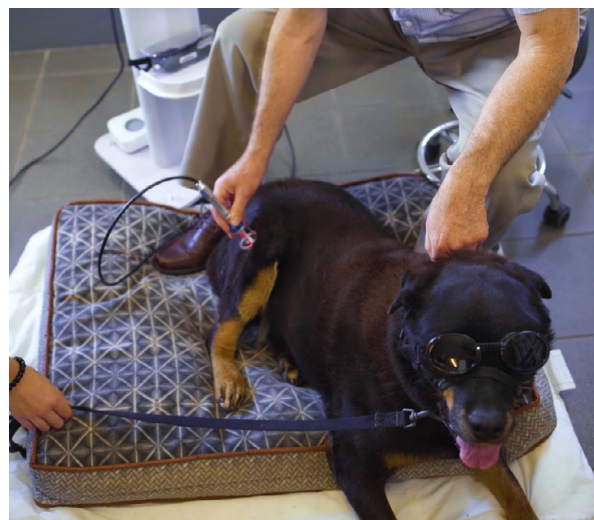

Figure 2.

the morning after his first laser session, to spend the next 24 hours chasing his 5 year old female mastiff companion around the garden...!

Our current biggest fan is a 50+kg Rescued Mastiff, who has gone from being wary about vet clinics to now refusing to leave after his laser session. We have a hilarious video showing how we have to exit the clinic first, then slowly reel him out the front door—otherwise he will not budge past the reception desk.(Figure.3)

Practical Tips

To make PBMT/Laser therapy work for your practice, you do need to invest some time in educating yourself on what the laser can do and how to make it work for you.

Not all laser machines are equal. We did our



Figure 3. Watch video in eBook

research before purchasing our first machine. We could have purchased cheaper, entry-level lower intensity class 4 machines—the downside of which was the huge staff-time investment those slower machines require.

In a veterinary setting, Power and Treatment Time are the ingredients for usage and success. Less powerful machines require longer treatment times to provide the correct treatment dose.

Treatment plans are based on JOULES per sq cm(i.e. dosage).

One Joule=1W/sec.

This effective dosage applied to tissues will be controlled by:

Light Wavelength: the commonly used wavelengths are 810nm and 980nm as they produce the best penetration of tissue

Power/Time

Case Examples

600J is suitable for a small dog iliopsoas/I.V.D.D presentation.

A 1W Class 4 machine will need a 10 minute treatment time versus a Class 4 Laser like the 30 Vets1Laser easily delivering 5W needing only TWO minutes.

Consider if you want to deliver 1600J to a larger dog i.e. a 30kg dog.

A 1W Class 4 takes 26:40 minutes versus 30W Vets1Laser, delivering 8W, takes only 3:20 minutes.

For even larger animals, you simply increase the power, without needing to increase the time.

Most animals will sit still for up to 5-8 minutes; Vets can fit in lots of 3-8min laser sessions in a day's work. However, neither the pet nor the vet nor the tech nurse are quite so keen when asked to sit or reduce productivity for up to 30 minutes at a time, as happens with less powerful, cheaper machines.

High intensity machines can do all that a low intensity machine does, plus it has the scope to increase power to treat a wider range of patients and ailments.

Clipping of the patient's coat

This is not necessary when using the Vets1Laser: a big bonus for saving time and also reduces an owners reluctance to try the procedure. However, other machines may require shaving the pet, so check the fine print on your machine of interest.

Formal Education & Training

Information and training are easily accessed. An excellent foundation for using this technology would be the on-line course 'Introduction to Companion Animal Laser Therapy' from AIMLA (American Institute of Medical laser Applications).

The reference text 'Laser Therapy in Veterinary Medicine: Photobiomodulation' is also available from AIMLA and on-line.

Additionally, there is a wide range of published articles on-line on this therapy, both in the human and veterinary field. However if any *C&T* reader wants more customised information, happy as always for *C&T* readers to do what they have always done, email me about an article directly on; vets@oakflatsvet.com.au Or alternatively, just for this topic, via the contact form at <https://Vets1Laser.com>.

Finally

I am well aware that currently my own personal clinical findings shared above are totally observational/anecdotal. However, all scientific knowledge starts first with observation.

Almost all of my other 17 scientific peer-reviewed publications started from an observation in a clinical practice setting. I aim one day to add some of my laser 'observations' to both my own and others peer-reviewed papers list, so watch this space.

I hope this article fires up some positive passion in those reading it.

My apologies if you have negative opinions of my actions—I do understand where you are coming from. I too have been conflicted.

I was very reluctant to name specific prices or name the Vets1Laser machine initially.

I had wanted the articles to be focused on the therapy not the machinery. I had to be convinced that it would make the articles more useful to the *CVE*-reader if those details were included, so I have now supplied that data.

In the end, the benefits of my sharing my findings made it impossible not to do as I have always done for the last 15 years; shared my thoughts and findings with the *C&T* readership.

Photobiomodulation reading list

1. Laser Therapy in Veterinary Medicine:
Editor(s): Ronald J. Riegel, John C. Godbold Jr.
First published: 25 March 2017
Print ISBN: 9781119220114 | Online

2. Perilesional Photobiomodulation therapy and physical rehabilitation in post-operative recovery of dogs surgically treated for thoracolumbar disk extrusion. Bruno, E., Canal, S., Antonucci, M. *et al* *BMC Vet Res* 16, 120 (2020). <https://doi.org/10.1186/s12917-020-02333-3>
3. Effects of laser power, wavelength, coat length, and coat colour on tissue penetration using Photobiomodulation in healthy dogs. *Can J Vet Res.* 2020 Apr;84(2):131-137.
Lindsay N Hochman-Elam 1, R Eric Heidel 1, Justin W Shmalberg 1
4. Laser and radiosurgery in veterinary dentistry; Jan
Vet Clin North Am Small Anim Pract. 2013 May;43(3):651-668.
Doi: 10.1016/j.cvs.2013.02.012.
5. Penetration depth study of 830 nm low-intensity laser therapy on living dog tissue
Naruepon Kampa 1, Supranee Jitpean 1, Suvalak Seesupa 1, Somphong Hoisang 2
DOI: 10.14202/vetworld.2020.1417-1422
6. Effects of High Intensity Laser Therapy in the Treatment of Tendon and Ligament Injuries in Performance Horses. *Animals* (Basel). 2020 Jul 31;10(8):1327. Doi: 10.3390/ani10081327.
7. Management of Primary Injuries of the Medial Collateral Ligament of the Carpus in Two Horses.
Laura Quiney 1, Rachel Murray 2, Sue Dyson 2
J Equine Vet Sci. 2020 Mar;86:102878. Doi: 10.1016/j.jevs.2019.102878 ♦

EMAIL
UP-TO-DATE? @

CVE Members-the eBook is emailed to you on the 15th of Dec, Mar, June & Sept to coincide with delivery of the printed C&T.

Watch the videos and read/download the references from the eBook version.

cve.edu.au/control-and-therapy

Small

OUR K-LASER EXPERIENCES

Lynne Bodell

Bodell Lynne Veterinary Clinic

56 Chaston St, Wagga Wagga NSW 2650

+61 2 6925 5570

info@lynnebodellvetclinic.com.au

C&T No. 5906

We have been using the K-Laser now for coming on 3 years. I initially came across the K-Laser when I needed to replace an old laser machine which I had been using previously for acupuncture on horses.

I organised a demonstration of the machine with the representative and to be frank, when I was initially told the cost I thought it was unlikely that I would purchase one; however, I am very glad I did. When I read the multitude of uses they suggested for the K-Laser, I was sceptical to say the least. I think what changed my mind was that during the demo, the rep asked if I had any injuries to try it on. I had a strain injury of several months' duration in my knuckle (courtesy of a difficult sheep) which niggled me, so she lasered it. Within 24hrs I was not noticing it anymore (and to date have only had to treat it once more), so that pretty much changed my view of the K-Laser.

I have used our machine on cats, dogs, horses and humans. I use it predominantly for the anti-inflammatory effects and increased wound healing and not so much for acupuncture now (although it can be used to stimulate acupuncture points).

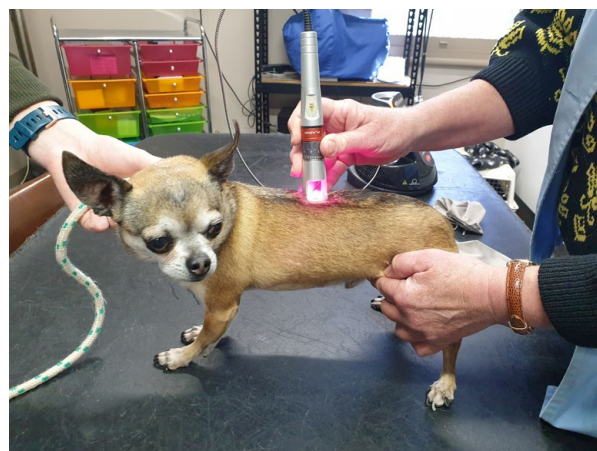

Figure 1. Ronald in for his monthly laser for back pain

My initial cases were on HUMAN friends, family and staff, to get an idea of frequency and duration of effect and that it DID WORK!! What we found in people was that on the typical program of 3,

2,1 (i.e., 3 sessions first week, 2 in the 2nd and 1 in the 3rd), there was almost no change in pain after the first 2 sessions; however, by the 3rd session they reported feeling better and then the improvement continued for each session after that. (The conditions treated were generally chronic problems—knee arthritis, back pain, ankle pain, etc.).

I think for chronic conditions in dogs and cats the response time is similar as far as we can determine. Certainly, there is no issue in using it on animals because there is no discomfort involved and it is a pleasant sensation.

Obviously, we charge a consult fee to assess the animal; however, after that, I don't actually charge very much because I find people are then happy to keep coming back for regular treatments. I normally only charge between \$20 and \$35 a session (depends how many areas need treating). The actual treatment times are generally only 2-5 minutes per area (can only do a max of 3 areas per day, e.g. back, hip and elbow, but most are generally just one area so average 3 minutes). Nurses can also have training and do the treatments.

We often slot these in between appointments, as they are really quick and easy and don't take much more time than taking sutures out.

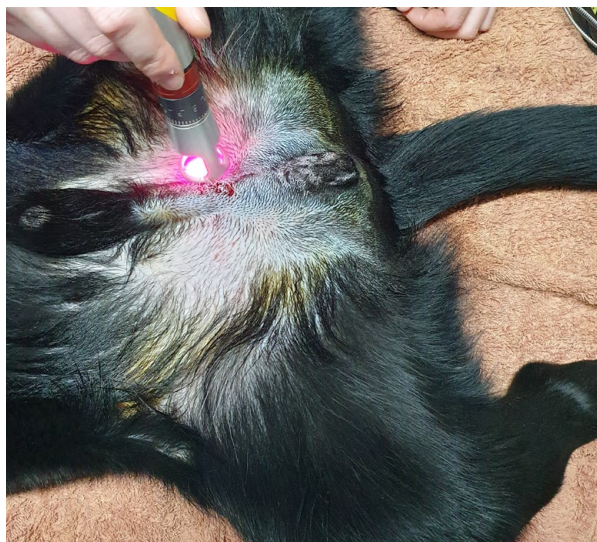


Figure 2. This is Arlo, a Labrador, receiving laser immediately following his desexing surgery to promote wound healing and reduce inflammation. Post desexing we would not do a follow-up laser treatment.

Once the initial course has been completed, if it is an ongoing problem we find once per month is generally sufficient to maintain the pain relief. (I have some clients who now phone and ask if they can drop by to have their knee done when it flares up—great for client relations!)

For wounds, I have noticed that we get less swelling and inflammation post operatively. It is also recommended for use after dental extractions which I should use it more on but have not yet done so.

Some examples of what we have successfully used the K-Laser for:

- Acute and chronic back pain, Intervertebral Disc Degeneration (IVDD), post spinal surgery
- Arthritis (esp. old animals where NSAIDS risky, often can reduce amount other meds needed)
- Wound healing - post op (strongly recommend), non/slow healing horse leg wounds
- Tendon injuries in horses
- Tendonitis in dogs

There are dozens of other uses, which we have not tried it on yet but probably will. When I first made enquires with other people who had the K-Laser they also recommended them, although they commented that occasionally you get the odd case that you think should respond and for some reason it doesn't. I would agree with that, but it is not often.

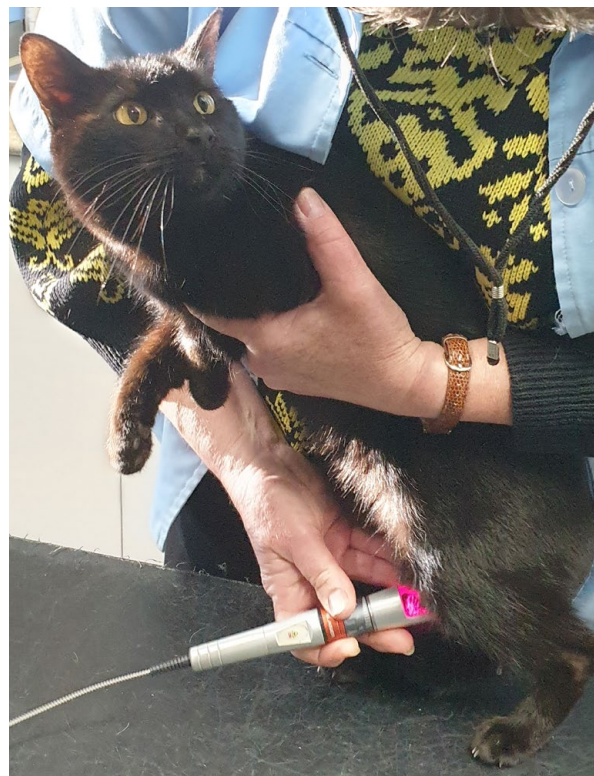



Figure 3. Sakari has monthly laser for stifle arthritis



This video (viewable in the eBook version) is of Adel—my Rottweiler who had chronic forelimb lameness of 3–4 months’ duration due to elbow flexor enthesopathy. She had not responded to NSAIDs. Prior to starting on laser, she would have been about a grade 3/5 lameness in the right foreleg; following the full laser treatment and now continuing weekly for a while longer, she is about a grade 1/5 lameness.

It is not a magic wand, but I certainly think it gives us another option for some and enhances healing for others.

In hindsight, would I purchase one again? Yes, absolutely! And when I retire, it is going with me!

If anyone would like to discuss a case, I am happy to do so and would love to hear other people’s experiences

Happy K-Lasering !!!!! ♦

LASER THERAPY

Ray Ferguson

Australian Greyhound Working and
Sporting dog Veterinarians
Monash Veterinary Clinic

1662 Dandenong Rd
Oakleigh East, VIC 3166

monashvet.com.au

rayferg@bigpond.net.au

C&T No. 5907

Basically, my experiences are similar to Lynne’s.

Lasers have been around in greyhounds (GH) and show dogs for a long time. The original ones were low power infrared beams, which I could not get a positive response from. They were upsold by the laser vendors but did not become commonplace. Most were class 2 lasers.

Lasers are classified by their power

- Class 1 & 2: Visible light power < 1 milli watt
- Class 3B: 5– 499 milli watt can cause eye damage
- Class 4: > 500 milli watts can cause eye damage

Some people prefer to call laser therapy ‘light therapy’ or ‘Photobiomodulation’.

Physiotherapy devices have been used in the greyhound (and horse) industry for many years. Trainers preferred anything with a quick fix or minimal input from them.

Some trainers have persisted with therapeutic ultrasound. This is time consuming, and I really wonder about its efficacy as the dogs are not clipped and so contact is often poor (you realise this once you start doing diagnostic US). Magnetic field therapy is popular. A blanket or other device is put on and the dogs either stand or lie down for 15–20 minutes. This is easy for the trainer and the dogs enjoy it.

The dry and wet needling techniques that had been developed continued to be used by veterinarians and lay practitioners. Again, quick, and easy.

Chiropractic work, Bowen therapists, acupuncturists and massage therapists are also in some demand for working and show dogs.

I became interested in Lasers when the more powerful class 4 lasers started to appear. Various manufacturers had identified veterinary practice as a market, and it seems there is a big uptake in North America.

I went to various seminars and read about them. To me there was a lot of black magic and sales pitch. DLC offered me their ASA multiwave class 4 laser to trial and so I took it and used it over 4 weeks on 10 arthritic dogs. I achieved an 80% response. This machine was \$16K. Others such as the K-Laser are about \$30K I think.

I convinced the practice to buy it for me. We charge \$50 per session, and it paid for itself within a year.

Uses are the same as Lynne outlines. I have also treated a couple of lick granulomas successfully. I am the main user in our practice as I only work in the field of arthritis / lameness. Younger vets can pick up laser therapy but they are often feeling their way with NSAIDs etc. Its potential use is huge.

Malcolm Ware and Rebecca Ainsworth who have a successful rehab / physio practice at Whittlesea have 3 lasers I believe.

In my greyhound and lameness practice it is wonderful because I do not have to dry or wet needle dogs. This means the dogs don’t hate coming to the vets. I have trained up some nurses to do the treatments.

In the greyhound world (and the equine world) there seem to be more trainers with lasers. They tend to buy class 3B lasers from Laserex in Adelaide for \$3.5K.

laserex.net There is still a lot of sale pitch that comes from them.

You can also get the Vets1Laser from Vetsone for round \$18k (it is a 30W Class 4 machine)

I find nothing in Lynne's article that I disagree with. She has sensibly noted it is not a cure all. There is a lot of good literature supporting the use of lasers and their mode of action.

At the Australian Greyhound Working and Sporting Dog Veterinarians online conference this year we have Dr. Steve Fearnside speaking on their mode of action and indications.

The advent of solid rehabilitation and physiotherapy diplomas from the USA have helped put a lot of science into this field and dispel the black magic.

I also note that the Australian College is developing chapters in equine and canine sports medicine.



Note: Proceedings No. 427 Sports Medicine: Theory & Practice (2016) featuring Debra Canapp DVM DACVSMR CCRT CVA and Sherman Canapp DVM MS Diplomate ACVS DACVSMR CCRT is available to CVE Members in the CVeLibrary. ♦



Winner – Best Visuals

Entitled to a digital video or DVD from the CVeSHOP

General

ORPHANED MOUNTAIN LION CUB SUCCESSFULLY TREATED FOR BURNS SUSTAINED IN DEADLY CALIFORNIA WILDFIRE

Dr. Stephanie McEwan

University of California

Medicine and Surgery

Irvine, California USA

C&T No. 5908

Cover image courtesy of fox40.com

Last September, a crew of firefighters spotted a lone limping male mountain lion cub that had sustained severe burns secondary to one of the deadliest wildfires in the history of California (the 'Zogg Wildfire'). It was unknown whether the cub's mother had perished in the wildfire or had become



Figure 1. Air support dropping fire retardant on the wildfire. Photo courtesy Hung T.Vu /Special to the Record Searchlight.



Figure 2. 'Zogg Wildfire' in Northern California. Photo courtesy Wildfire Alert

Figure 3. 'Zogg Wildfire' in Northern California

Figure 4. Captain Cal (left), Poppy (center) and Goldie (right). Photo courtesy of collaboration between Oakland Zoo and Columbus Zoo.

Figure 5. The mountain lion cubs living in their forever home at the Columbus Zoo. Photo courtesy of Amanda Carberry, Columbus Zoo and Aquarium.

Figure 6. Captain Cal being examined at Oakland Zoo Veterinary Hospital – all four feet sustained severe burns. Photo courtesy of Oakland Zoo.

Figure 7. Captain Cal was admitted to the Oakland Zoo Veterinary Hospital for emergency medical care and treatment after being rescued from the California wildfire. Photo courtesy of Oakland Zoo.

Figure 8. Captain Cal was eventually introduced to two mountain lion sisters to begin bonding. Their initial encounter was successful, and Captain Cal seemed comforted by their presence. The two female cubs were also orphaned by the California wildfires. Photo courtesy of Oakland Zoo.

Figure 9a & 9b. Captain Cal receiving milk formula at Oakland Zoo Veterinary Hospital plus pain medications and advanced wound care. Photo courtesy of Oakland Zoo.


Figure 10. Photo courtesy of Oakland Zoo. Captain Cal with his two adopted sisters. Captain Cal is in the far-right side of the photo. All three bonded cubs were eventually transported to their new home at the Columbus Zoo.

Figure 11. Captain Cal in Oakland Zoo Veterinary Hospital with bandaged feet. Removal of dead skin from each wounded foot allowed antibiotics to work on the infected areas. Then each foot was re-bandaged to facilitate healing. Photo courtesy of Oakland Zoo.

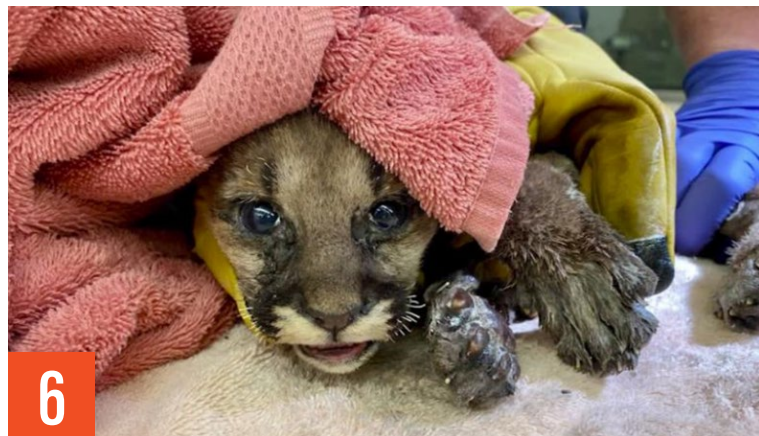



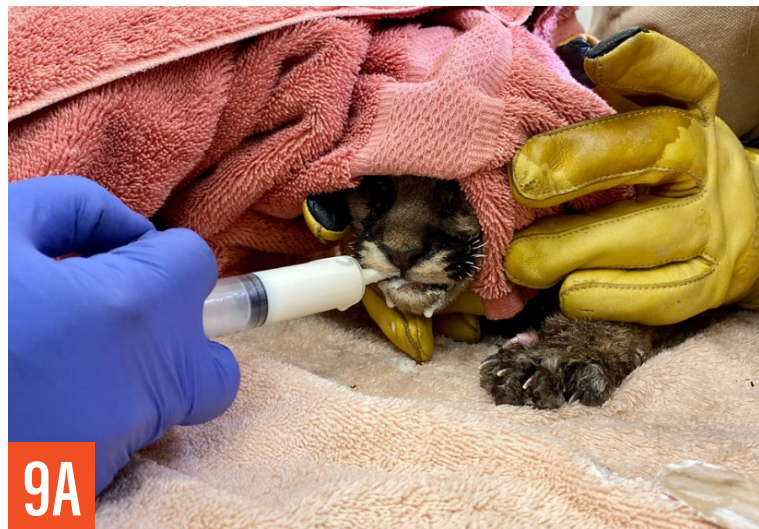3



5



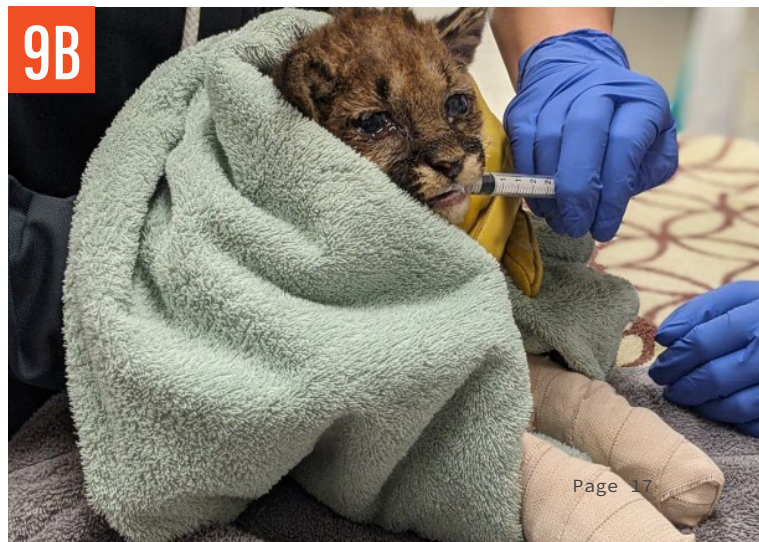
6



9A



11



9B

separated from her cub because of the intense fire and smoke, and simply could not find him again.

Upon discovery, the orphaned cub was noted to have bone visible between his burned toes, as well as severe soft tissue damage to all four paws, singed whiskers, eye irritation, marked emaciation and dehydration. The firefighters named the cub 'Captain Cal' and made swift arrangements with California authorities for transportation of the injured cub to the Oakland Zoo Veterinary Hospital in Northern California for emergency care and treatment.

Following triage at the Oakland Zoo Veterinary Hospital, the little cub's age was estimated to be around 4-6 weeks, and his weight was only 3.75 pounds (1.7 kg). The Director of the Zoo's Veterinary Hospital (Dr. Alex Herman, DVM) and several wound care specialists from the University of California Davis Veterinary Medicine Teaching Hospital (including Dr. Jamie Peyton, DVM) formed a collaborative team to discuss Captain Cal's medical care and treatment.

Upon admission, Captain Cal presented with severe burns to the pads of all four paws and was unable to walk; his physical condition was considered critical. In addition to receiving emergency treatment for severe burns to his paws, the zoo's veterinary team initiated round-the-clock medical care for Captain Cal, including administration of supportive fluids, pain medications, antibiotics, and feedings (milk formula for kittens fed through a syringe).

The cub's badly burned necrotic paws were regularly debrided and carefully treated, eventually leading to new skin regeneration. According to Dr. Alex Herman, complete 'debridement and bandaging with Manuka raw honey and Medihoney bandages caused rapid infection control and re-epithelialization to occur.'

After 6-8 weeks of dedicated medical care and treatment, the outcome was positive; and Captain Cal was well on his way to a successful recovery.

In the wild, mountain lion cubs typically spend a few years with their mother to learn how to hunt for food and survive on their own, before venturing forth alone. Otherwise, a young cub has not learned enough basic living skills to survive in the wild alone and needs a continuing source of food and safe shelter.

Having been orphaned at such a young age, Captain Cal could not be released back into the wild for his own safety and survival. So, as soon as the young mountain lion was ready to be discharged

from the Oakland Zoo Veterinary Hospital, he was transported to his new home at the Columbus Zoo in Ohio, USA. He was joined by two female mountain lion cubs (named Goldie and Poppy) that had also been orphaned from their own mother in the deadly California wildfires. All three cubs bonded together at the Oakland Zoo before arriving at the Columbus Zoo.

As you can see from the latest photographs, all is well with Captain Cal and his two adopted sisters, in their new forever home at the Columbus Zoo! ♦



Download 3 articles on Manuka Honey from the CVELibrary

- C&T 4313a, Jun 2002, Liyou O, Honey in wound management, Issue 225
- C&T 5168, Mar 2011, Proud Flesh, Wong L & Andrews J, Issue 262
- C&T 5467, Sep 2015, Feary D, Comment on Leg Wounds in Horses, Issue 280

Avian

PURE BREEDING AND GENETIC CRUELTY IN AUSTRALIAN EXHIBITION BUDGERIGARS

Don Burke OAM Director Ctc Productions Pty Ltd

+612 9654 9277

db@burkesbackyard.com.au

C&T No. 5909

Abstract

This article looks into the problems with crossing 100% pure Australian Heritage Exhibition Budgerigars (AHEB) to modern exhibition budgerigars. AHEBs are bred to the very moderate Australian National Standard of 1962.

If breeders cross AHEBs to modern show birds to get 'better feathering', they will possibly be introducing the gene for Mop (AKA Feather-Duster) budgerigars, plus the genes that facilitate the Flightless and Tailless Wonder viruses, and others that create difficulty and pain in flying and a susceptibility to wing feather cysts.

Breeding for larger size in budgies turns them into 'High Response' breeds like meat chickens, meat pigs and thoroughbred racehorses. Put simply, High Response breeds grow very large very quickly. But they must be fed a 100% perfect diet, otherwise things go wrong developmentally. But even if they are perfectly fed, problems with arthritis issues, distorted limbs, and generally short lives, are common.

It is the thesis here that, in general, it is prudent not to change the basic developmental geometry and fundamental growth rates too much from the wild type of any animal. Particularly in birds.

If fundamental changes are to be attempted, ongoing expert veterinary advice and assessments should be sought from specialists nominated by the appropriate universities.

To do other than this is to become involved in Genetic Cruelty, which will inevitably lead to Government action, sooner or later. It is put forward here that Genetic Cruelty is perhaps the world's biggest animal cruelty issue, yet it remains largely overlooked. There are currently about 26 billion poultry in the production industry worldwide. Meat pigs, meat chickens and thoroughbred racehorses in particular are bred to have very fast growth rates, which often condemns them to lives of pain and misery, particularly with chronic joint problems. Modern Exhibition budgies are just one problem species to look at.



Figure 1A. Australian Heritage Fallow Clearwing Amethyst

There has been a recent tendency to outcross Australian Heritage Exhibition budgies to modern showbirds 'to improve them', so I thought that it would be a good idea to look at this in detail.

Firstly, are modern showbirds better than 1962 Heritage Exhibition budgies? No, they are not.

These are just two different arbitrary standards that two independent groups breed to. Are large, modern heads, long masks, wide shoulders, etc. better than the smaller overall size, smaller heads, narrower shoulders, shorter masks etc. of Australian Heritage showbirds? No, they are not. They are just 'Breed Standards' like the different standards for Poodle and German Shepherd dogs: both breeds are dogs, but they are bred to different standards.

If you cross your Heritage Exhibition Clearwings to modern showbirds, it is the Australian Heritage Budgerigar Association's contention you will do great damage to the Heritage Clearwing breed. It has taken dedicated breeders over 90 years to get them just right. Just like crossing a Poodle to a German Shepherd. Imagine trying to re-create a poodle by breeding from that hybrid puppy.



Figure 1B. Australian Heritage Clearwing Violets



Figure 1C. Australian Heritage Clearwing Violet Dark Greens.

Figure 1. Above are Australian Heritage Exhibition Clearwing Budgerigars - preserved genetically from 1962. Beautiful colours and a body not too far changed from their wild ancestors. Healthy, functional budgies.

Australian Heritage Exhibition Budgerigars are much closer to the shape and size of a wild budgie. Does this matter? Yes, it does. If you change the size, shape or feathering of any bird, you can do enormous damage to its ability to fly or to its basic health and wellbeing.

For these reasons, it is essential to monitor the basic functionality of any birds that are bred to conform to artificial man-made standards (apart from colour). The greater the change in shape, size etc. from the wild type, the greater the need to check out the welfare of the bird. In an Ideal Bird Society, there would be a scientific advisor to whom new changes could be referred, for assessment of the welfare impact of the proposed or ongoing change. This has never occurred to my knowledge.

Feathers

Changing the density, length, and breadth of budgies' feathers may well be the greatest welfare problem that budgies have ever faced. Extremes in any physical aspect tend to cause breeders to grab onto nasty and cruel mutations that ruin animals' lives. Sadly, these breeders are often totally unaware of the hereditary cruelty that they have created. Take Mop or Feather-Duster budgies: these are caused by an obsessive compulsion to breed ever longer and lusher feathering in budgies. Heterozygous Mops have 'superbly' long and lush feathering. Homozygous Mops are as described: a Mop—they are dysfunctional and are usually destroyed. But you can breed super long and lush feathering without using the Mop gene. If all budgie breeders culled all Mop producers, soon we would have budgies with the required feathering without carrying the Mop gene. Everyone wins!!!

If you mate Heritage clearwings with short flight and tail feathers, to this bird in Figure 7 with short flight and tail feathers (but long feathers everywhere else) together, you will get 100% of babies with LONG flight and tail feathers! (and reasonably long feathers everywhere else).

But there are still problems with long feathering that is not based on the Mop gene. In general, it is based on one semi-dominant gene. But this gene lengthens ALL feathers on the budgie. Long head, mask, and body feathers appeal to most breeders; however, the associated long flight and tail feathers are quite ugly to most people (see Figure 6). They also hinder flying ability. So unknowingly, European breeders incorporated a recessive gene that left most feathers long and lush, but shortened the flight and tail feathers, which fixed the problem. But it came at a price. From my research, this gene appears to weaken the growth of the flight and tail



feathers, possibly predisposing to both Flightless and Tailless Wonders and also perhaps, wing feather cysts (See Figure 9).

I have never had wing feather cysts on any Pure Australian Heritage budgerigar or on a Pure bush budgie. The wing feather cysts may also relate to overly Buff (i.e., luxurious, and dense) feathering. This overly-Buff development in Norwich Canaries caused wing feather cysts from 1925 to 1935. It was eradicated by selecting for finer-feathered Norwich canaries in the 1950s. This involved a 'heated controversy' within the Norwich Canary



4



5



7



6

Figure 2. This is a UK modern Exhibition Budgerigar. It is very far removed from the wild type of the budgerigar. It has almost no forward vision and would fly with great difficulty.

Figure 3. This, believe it or not is a live budgerigar. It is a Feather Duster or Mop. It is the result of extreme breeding for ever-greater amount of feathering.

Figure 4. Severe feather cyst on a budgerigar's wing. This is caused by overly-dense feathering. That is, it is highly heritable.

Figure 5. Both photos above depict budgies with long flight feathers. They are the result of outcrossing Australian Heritage Exhibition Clearwings (one a Rainbow clearwing) to modern exhibition budgies. The recessive flight and tail feather modifier gene which shortens flight and tail feathers in the modern bird produces this surprise when you mate Heritage to modern budgies.

Figure 6. Very long primary flight feathers: the tail feathers would also be very long. Commonly, breeders frame out the excessively long tails (as has happened here) to avoid embarrassment.

Figure 7. This modern European show bird has short flight feathers, but long feathers everywhere else: particularly on its over-sized head.

Figure 8. This pair of Heritage violet Clearwings has been caught mid-action in rapid, blurry courtship. The hen on the left, has perfectly-conformed wings. That is, they correspond precisely with the shape and proportions of the wings of wild budgerigars. Note the sleek satin-like feathering all over, even though they are in a heavy moult. These Heritage budgies are every bit as athletic and healthy as wild budgies are.



8

club (see 'Budgerigars Canaries and Foreign Finches' by R.B. Bennett 1961 pp 186-7). This canary problem precisely forecasts the current problems of excessive feather and body size in modern exhibition budgies.

There appears to be two common feather-loss diseases in exhibition budgies, which are quite different in symptoms. Both seem likely to be caused by a virus, but more research is needed to identify which virus is involved in each disease. In an endeavour to sort out which virus does what in budgerigars in Australia, we are planning to collect feathers from (i) Birds with French moult, (ii) birds which are Flightless and Tailless Wonders (F&TW), plus (iii) non-affected birds as a control, and to do DNA identification (PCRs) of the viruses involved. We hope to have this done by the end of 2021, depending on COVID.

- The first feather loss disease is called **French Mould**. It mainly causes wing and tail feather loss as the babies leave the nest, and from which they almost always recover in around 3 weeks. A small percentage may lose most of their feathers and not recover, and some infant mortality may also occur in the nest as well. All budgerigar varieties may get this disease.
- The second disease is called **Flightless and Tailless Wonders** (F&TW). This disease also causes wing and tail feather loss, but this does not begin until the birds are about 12 months of age. This condition continues to get worse over the ensuing months, and none of these birds will recover. In my experience only Modern excessively feathered UK and European budgies show the symptoms of this disease.

My suspicion with F&TW birds is that the heavy feather production also leads to a weakening of

feather growth which facilitates the development of the disease symptoms such as permanent feather loss. It is also very likely that the recessive gene for short flight and tail feathers that I have discovered plays a major part in the occurrence of F&TW. I have never had a single F&TW amongst my bush budgies nor with my 100% Pure Australian Heritage Clearwings, despite my cross-fostering and experimental mixing of F&TW birds amongst the bush and Heritage birds in aviaries. Here I am talking about 4000 bush and Heritage birds over 30 years. I suspect that many budgies of all types may well contract the F&TW disease, but that the Bush and Heritage types deal with it very well, with no feather loss nor any other worrying symptoms.

But whatever is discovered in the years to come, it is quite definite that the F&TW disease only causes Tail and Flight Feather Loss in the lines of modern showbirds imported from the UK and Europe. That is, it is an entirely avoidable disease.

In many modern show budgies, the Ala Spuria (bastard wing) hangs down, thus flight is inefficient as well. The Ala Spuria works very similarly to the bent-up wing tips on modern aeroplanes. It minimises turbulence in flight (see Figure 10).

Other Problems with Flight

The 'desirable' wide shoulders demanded in the current Standard of 'Perfection' almost certainly stretch out and/or distort the bones supporting the wings (such as the coracoid and scapula). The greatest likelihood here is arthritic problems due to stress from overly long or poorly conformed supporting bones. From as early as 3 months of age, many modern show birds increasingly remain on the aviary floor all day, presumably due to the pain involved in flight. X-rays might confirm this, one way or the other.

Directional Feather

Directional feather is the name for elongated feathers beside the cere (nasal area) in budgies. This elongation of previously short feathers in front of the eyes, seriously impedes forward vision. This sort of thing may be semi-OK in Old English Sheepdogs, because they can walk slowly and thus avoid walking into objects. But if birds fly slowly, they stall in flight, crashing into the ground.

For those who breed larger, modern showbirds, please note that most of these problems can be eradicated fairly easily. The best option is to cull all birds that produce Feather Dusters, as these parents are carriers of this effectively recessive condition. You can easily breed coarse feathered birds without using the feather duster gene. Many modern showbirds already have coarse feathering



Figure 9. Flightless and Tailless Wonders. They never recover from this condition.



Figure 10. This bird has directional feathering which impedes forward vision. You cannot even see its eyes. Note the yellow dagger feathers either side of its chest. These are distorted Bastard Wings (Ala Spuria) that can no longer aid in stable, efficient flight.

without the FD gene. Buying birds from the ethical breeders of these types of birds (i.e., breeders who assure purchasers that they never produce any Feather Dusters) is advisable.

Extremes in all things are genetically dangerous. A nicely finessed show bird with good wing carriage, deportment, colour, and markings, combined with not too much feathering is a superb sight. Extremes are just a mess, and an unhealthy mess at that.

On the right is the AHBA's Perpetual National Standard of Perfection. Points are lost if a bird has a greater or lesser length than 8½ inches (216 mm). Note that the flight feathers must be just a bit shorter than the rump body feathering. Any features that are in excess of the Standard will be penalised equally to features that are less than the Standard. Extremes of feathering and size are to be avoided.

Working with Veterinary Experts

It is long overdue for Breed Clubs to work with appropriate Veterinary Experts in the various disciplines so that birds and other animals can 'Have the Look' or 'Produce the Goods', without living a life of discomfort and misery. Without any significant physical changes to look or performance, animals can be produced that are

truly amazing, when leading breeders collaborate with Veterinary Scientists. This sort of thing happened informally in the past with brilliant Vets like Dr Len Pockley (cattle), Dr Derek Major (Horses), Dr Harry Spira (dogs) and more recently, with Richard Malik DVSc (cats). But they all did it as good citizens off their own bats. We need a system that ensures that this sort of monitoring and cruelty minimisation is the norm.

We need formal arrangements to ensure an ongoing improvement of balanced and functional excellence in all aspects of animal breeding.



Figure 11. This is one of John Hawke's beautiful Red Violet Australian Exhibition Heritage Clearwings. This bird has the outline, flight feathers, overall fine feathering, mask, and head as per the AHBA Standard of perfection (see Figure 12). His crouching stance is a due to the fear that all Heritage budgies feel in glass-fronted photo cages. Better to photograph between the wires of a show cage, using a smart phone. Budgies rarely cope well with glass-fronted cages.

Figure 12. The 1962 Budgerigar Standard of Perfection, adopted by the Australian Heritage Budgerigar Association to protect and preserve Heritage budgies. ♦

Small

MITOTANE—IS AUSTRALIA ABOUT TO LOSE THIS ESSENTIAL DRUG?

**Sue Foster BVSc MVetClinStud
FANZCVS**

+61 0423 783 689

sfoster01@bigpond.com

C&T No. 5910

Mitotane is a cytotoxic drug, usually dosed to cause a selective destruction of the zona reticularis and zona fasciculata of the adrenal glands in dogs with pituitary dependent hyperadrenocorticism. Higher doses can induce non-selective ablation of all zones and result in intentional (or unintentional) hypoadrenocorticism. It is also used as a palliative agent of adrenal adenomas and carcinomas.

For decades, it has been an established drug in the management of human adrenocortical carcinomas and is registered for this indication by the US Food and Drug Administration (FDA) and the European Medicines Agency (EMA). It is not however registered in Australia. This has had implications for both humans¹ and dogs. Mitotane has long been manufactured for dogs in Australia by Apex (formerly) and then Dechra (after acquisition of Apex) but available only by permit. Any veterinarian wishing to order mitotane has to provide a signed written request stating the veterinary surgeon's registration number, specifying the quantity of the product requested and containing the required statement regarding product use. So why would anyone bother? Any graduate of Australian veterinary schools for the last 5-10 years would only have ever been taught to medically treat hyperadrenocorticism with trilostane.

Trilostane is a great drug to use in many ways—no messing around with induction and maintenance and trying to explain the vagaries and variabilities in response to clients and it is easier to reverse (just stop it) however it is still not ideal. There is still worldwide debate over what constitutes good control, something that was settled decades ago for mitotane and there are significant safety concerns, with dogs still able to develop clinical glucocorticoid deficiency with or without mineralocorticoid deficiency either from excessive

dose or idiosyncratic adrenal necrosis (the latter sometimes occurring acutely in the first weeks of treatment). Trilostane is far from the safe and easily effective drug it was purported to be in the early 21st Century. In addition, it is very expensive and to be used safely, requires intensive monitoring, entailing even more owner commitment and expense. The product has achieved mainstream acceptance due largely to marketing, significant support from many specialist endocrinologists (many of which have research funding from Dechra) and ease of availability in general practice.

However, mitotane has clung on and it is still used by discerning specialist and general practitioners, for good reason: it still has an important place in the medical options for treatment of hyperadrenocorticism.

Advantages of mitotane:

1. It is considerably cheaper in small breed dogs to use mitotane compared to trilostane—it makes this disease affordable for those with financial constraints. To remove it will be to deny treatment options for lower income owners.
2. Once control has been achieved, patients on mitotane tend to have stable control for years thus only requiring twice yearly monitoring compared to the 3 monthly monitoring that is really required for safe use with trilostane.
3. For any condition requiring really stable daily control of blood cortisol (as opposed to fluctuating levels with peak and trough effects), mitotane is the ideal option. Such conditions could include Cushing's myotonia, some cases of calcinosis cutis, recurrent pancreatitis cases and hypertriglyceridaemic patients.
4. It allows a permanent cure of the condition—either by intentional or inadvertent non-selective adrenal necrosis to convert hyperadrenocorticism to hypoadrenocorticism (a disease that is much cheaper and easier to treat). Non-selective adrenocorticolysis is often successfully used by rural/regional practitioners whose clients do not necessarily live close enough for the regular monitoring tests required with trilostane or selective mitotane adrenocorticolysis protocols.
5. When dogs do not tolerate trilostane, mitotane is the only option other than bilateral adrenalectomy (for which there is a paucity of complication and mortality data). Trilostane occasionally causes severe idiosyncratic skin conditions reversible on discontinuation and sometimes also in some dogs causes lethargy, gastrointestinal signs and pain/discomfort (possibly adrenal pain

1. See: NSW Government. [eviQ-compliance-with-TGA-registration-and-PBS-listing-for-drugs-COMBINED-document-and-flow-diagram-v-2-0-July-2021.pdf](#)

and difficult to investigate and manage, but which resolves on discontinuation and does not occur when dogs are switched to mitotane).

The disadvantages of mitotane are many and well documented, including it being a chemotoxic agent with handling implications. However, there is no doubt that this drug is still important in Australia where hyperadrenocorticism is seemingly more prevalent than in any other country in the world.

But what about the myth that survival time is the same with and without treatment?

This sentiment is firmly labelled as an 'urban legend' in the current edition of 'Feldman and Nelson' (Behrend 2015). A 2018 study by Hoffman and colleagues showed that hyperadrenocorticism caused death directly or from other related diseases in up to 30.8% of a referral population. This data appeared skewed as deaths from functional adrenal tumours predominated but nonetheless the data indicated that hyperadrenocorticism is not a benign disease. This would be in line with a non-euthanasia-endpoint study in which trilostane treatment of pituitary dependent hyperadrenocorticism improved survival times (Nagata *et al* 2015). However, in addition to mortality concerns, hyperadrenocorticism causes significant quality of life and welfare issues (Schofield *et al* 2019). To end up with only one treatment option that is not affordable or potentially deleterious is most concerning.

So why is it happening?

Clearly no company can be expected to market a commercially unviable product, and younger practitioners seem either not to know the product exists, or its indications. In addition, it seems that APVMA is increasingly demanding companies with products on permit go through extensive registration trials for these important but niche products, something that no company could ever do.

So why can't we just get it compounded?

Compounding this drug is somewhat fraught in my experience. Mitotane is insoluble in water and the specification of particle size distribution is likely important for reproducible effects. **If Dechra stops manufacturing mitotane, hopefully at least they will consider licensing the manufacturing procedure to any compounder or other manufacturer interested to take on the product.**

What to do?

1. Contact APVMA and express your concern about the loss of niche products on minor-use permits. That a permit lasts for a long time doesn't mean the product has gone mainstream. Give your feedback at portal.apvma.gov.au/feedback
2. Contact Dechra (info@dechra.com) and detail why mitotane is important and why its loss to Australian veterinary patients would have a significant impact. Request that they continue their production or that if they do abandon the product, they consider licensing the manufacturing procedure to a compounder or other manufacturer that is interested to take on the product.
3. Contact the AVA.

References

Behrend E. Canine hyperadrenocorticism. In Feldman EC, Nelson RW, Reusch CE and Scott-Moncrieff JC (Eds). *Canine and Feline Endocrinology*. 2015

Hoffman JM *et al*. Canine hyperadrenocorticism associations with signalment, selected comorbidities and mortality within North American veterinary teaching hospitals. *J Small Anim Pract* 2018;59(11):681-690

Nagata N *et al*. Comparison of survival times for dogs with pituitary-dependent hyperadrenocorticism in a primary-care hospital: treated with trilostane versus untreated. *J Vet Intern Med* 2017;31:22-28

Schofield I *et al*. Development and evaluation of a health-related quality-of-life tool for dogs with Cushing's syndrome. *J Vet Intern Med* 2019;1-10 ♦

Small TO BLEED OR NOT TO BLEED?—THAT IS STILL THE QUESTION IN 2021...

Aine Seavers

Oak Flats Vet Clinic

58A Central Avenue

Oak Flats NSW 2529

reception@oakflatsvet.com.au

C&T No. 5911

It has been almost 10 years since I compiled information for C&T readers on the use of Vitamin K₁ in rodenticide poison cases in dogs. The original article C&T No.5216, 'To Bleed or Not to Bleed' became one of my most popular submissions. To this day, I receive calls from colleagues about treatment options in these cases.

The overwhelming impression clinicians and owners have of rodenticide poison cases is of the financial cost involved, even in an uncomplicated case. As I have had animals die from lack of

available finances, rather than from the actual disease syndrome, making treatment affordable and safe for any and every presentation is a passion of mine.

As Rodenticide poisonings still fall into the category of a possible financial euthanasia scenario and with the rodent plague from Summer 2020 looking to be rolling back around for Summer 2021, I thought it best to update the original article, given that a lot has changed in the interim years re costings and product options.

Treatment Regimes

Effective Oral Dose

The treatment oral dose of Vit K₁ on product labels of available patented and generic Vit K₁ oral products varies from 1.0-12.5mg/kg!

This reflects the difference in whether 1st generation or 2nd generation poisons are to be treated.

This Dose/Generation variation had not been clear on many Vit-K₁ product labels.

A. Warfarin/1st Generation (or what I like to call; Bedside Locker Poisonings).

Vit K₁ at: 2.5mg/kg subcutaneously (SC) in several sites, then 1-2.5mg/kg divided daily every 8-12 hours for 5-7 days (JSAP Formulary 2021).

or

0.25-1.0 mg/kg Vit K₁/kg/BW intramuscularly (IM), SC or orally (PO) in divided doses for 5-7 days (Woody JVIM).

or

0.25-2.5mg/kg /BW small dogs—0.5-2.5mg/kg/BW large dogs for 7 days.

Whilst we rarely see Warfarin cases from rat baits (such as Ratsak®) anymore, dogs will present having eaten their owner's Warfarin tablets.

It is important to keep the **ingestion of Warfarin in perspective**.

One must know not just the lag phase (2-5 days), but also the therapeutic dose and the acute and chronic poison dose in dogs should they ingest their owner's pills.

- A dosage regimen of Warfarin for anticoagulant therapy in the dog of 0.22 mg/kg to be given orally every 12 h resulted in a prothrombin time returning to control values by 62h after withdrawal of the drug.
- 5-50 mg/kg of Warfarin have been associated with toxicity.

- Cumulative toxic doses of Warfarin have been reported as 1-5 mg/kg for 5 to 15 days in dogs.
- Warfarin does not inhibit the Vitamin K enzyme complex; hence, supplementation for 7-14 days is all that is needed.

For most average size dogs, ingestion of a 3mg Warfarin tablet will not have the same presentation as if that same dog had ingested a 2nd generation rat bait or packet. Yet, I have had a 14kg young adult dog—having ingested one 3mg human tablet, be then subjected to a huge after-hours emergency vet bill; wherein the poor dog was given multiple doses of apomorphine to ensure none of the tablet ingested 40 minutes before was missed...

The dog was then given Vit K₁ injection and sent home on 2 weeks of oral Vit K₁ and also oral charcoal, with a blood test scheduled for 7 days later. MADNESS!

My view is that the case: could have waited until the morning: be given a Vit K₁ injection and been sent home with 10-12 days of Vitamin K₁ tablets. Ditch the charcoal.

B. 2nd Generation

E.g. Brodifacoum (most Ratsak brands), Bromadiolone (some Ratsak products) and Difenacoum (Talon, Mortein, Ratsak Fast Action, Pestoff Rodent Bait 20R, Klerat).

Dose/kg

Plumb (7th edn, 2011): A loading dose of 2.5-5.0 mg/kg PO followed by 3-5mg/kg divided and given PO twice daily.

or

The JSAP 2021 Formulary: SC; 5 mg/kg in several sites followed in 6-12hrs with 2.5mg/kg orally twice daily for 3 weeks.* (6-8 weeks, reference below).

Treatment Duration

Published treatment interval ranges from:

- 5-7 days for 1st Gen
- 5-24 days for 2nd Generation baits...
- Even 24 days for 2nd Gen may not be sufficient*

*Mount (AM J Vet Res 1989 50;10;) found no detectable levels of Vit K₁ but found prolongation of prothrombin time in a 2nd gen exposed dog, 3 days after a 24 day treatment regime ceased.

A critical period after therapy was days 27-32 when the coagulation system was still impaired, so that any insult to vascular integrity could lead to severe

haemorrhage. Dogs given 5mg/kg/day x 21 days were better at limiting pathogenic changes at day 26-36 post ingestion with lower increases in OSPT levels than dogs on 2.5mg/kg/day. Coagulation was resolved by day 32 in Mount's study.

Clinical practice feedback is that vets have had dogs, treated for 4 weeks successfully for some 2nd generations, then sadly succumb to fatal haemorrhage in the ensuing 2 weeks. Equally, there have been cases tested at 4 weeks which clearly showed aberrant blood results requiring a total of a 42 day treatment regime.

In Mooney *et al**article on Vitamin K₁ therapy; June 2020 AVJ :225-231, it is interesting to note that 2 (Brodifacoum, SureFire bait cases) of the 4 dogs in the study were discharged on 42 days of oral Vitamin K₁, following initial intravenous therapy on Day 0.

Scarily, when both dogs were blood tested at 3 days off all supplementation i.e. Day 45, both dogs had to have another 14 days of Vit K₁ prescribed.

These cases reinforce many front-line clinicians' belief, that the much-touted 28 days of treatment should be the minimum range, **NOT** the end-date for supplementation.

Other Treatment Options

Still SC for 24-48hrs if PO is not an option in a critically ill case...

In 2021, we have some new IV drug options that can change what we use in the first 26 hours, more on that below.

Extended Oral Vit K₁ Dosing Concens

1. Side effects from dosing for an extended period of time.
2. Cost outlay to the client.

– Side effects

Vit K₁ is perceived to be very safe.

A fat-soluble Vitamin, it behaves biologically similarly to a water-soluble Vitamin. It has a short half-life with no significant storage pools.

Mount's work found that in a cohort of normal dogs given higher doses of Vit K₁, higher serum concentrations did not reveal accumulation of Vit K₁ within the blood. Serum Vit K₁ levels plateaued in these dogs from day 8-25, presumed to be enzyme induction of the Vit K₁ enzyme complex and or other microsomal systems, which may have allowed for more rapid clearing of Vit K₁.

The Heinz body anaemia issue seems mostly traceable back to human infant reports.

One canine case has been reported in 1984.

Haemolytic anaemia is an issue with cats.

Equally, it was other formulations of Vit K i.e. Menadione/K₃, not K₁, that were implicated in adverse drug reactions.

- **Cost:** Supplementation *versus* Surveillance testing.

The following comments are not a plug for any one product.

I am commenting simply based on purchase price. Finding affordable care for a client on limited funds is a daily reality of practice for those of us battling it out at the front-line of first opinion practice. The 'Gold Standard' protocol of daily PT/APTT testing to determine treatment duration is simply not affordable for the average owner.

The majority of poison cases are small to medium size dogs.

A single lab test, costed out at the laboratory base price, can represent 10-24 days of drug treatment for a small dog even before any professional service time for the consultation and blood collection is added. **As a result, on-going serial blood sampling can far exceed the cost of the actual lifesaving part of the therapy: the vitamin supplementation treatment.**

In 2012, a new **50mg** chewable tablet became available. Back in 2012, this product was very affordable and is super palatable. The high owner compliance with this Mavlab product must be due, in-no-small-part, to the 'treat'-like appearance of the chew. This 'treat' visual allows the guilt-racked owner to feel better about 'treating' their poor poisoned pet.

However, since 2012, the cost of several Vit-K formulations has increased considerably, resulting in a major impact on my **Testing Vs Treatment Cost/Benefit analysis equation.**

Then, this Spring 2021, a new player—**Kelato** brought to the market a K-Vet **80mg** x 42 tabs at the same price as the Mavlab 50x50mg bottle. In cases where lack of funds is a major concern, the 30%+ saving with the 80mg begins to tilt the financial equation back to favouring treatment over testing.

Administration Routes

1. Faster Speed of Oral versus Injection?

There is a new trend to avoid injections completely and start oral therapy. The theoretical benefit of oral, as Vit K is a fat soluble vitamin, is that the whole dose goes straight to the liver in the portal blood.

I have concerns with this oral medication only approach. With a haemorrhaging patient, there is every chance gut perfusion will be reduced; hence absorption from the oral dose could be impaired.

Add to that the fact that many haemorrhaging dogs present as/to an emergency scenario/clinic, wherein you may not have their previous history and don't know if this patient is a malabsorber or cholestatic, in which case oral meds are not a good idea.

Equally, whilst I personally have never induced emesis in these cases (an approach supported by toxicologist Dr Rhian Cope CVE Poison Treatment Perspective—rat baits come up out of the stomach dangerously hot), many vets do make these cases vomit. One has to then try to get the dog to take the vitamin chew, voluntarily, to preferably avoid any restraint for pilling etc. For me, this oral approach throws up too many obstacles and time delays to even consider replacing the fast effective immediate injection on presentation option with a per os option.

I will stick with what has yet to fail me across 2 hemispheres; If in doubt, '*Injection over pilling*' has been my motto across most things especially for pain and poisoning presentations. Once I have both a stable patient and the information re its medical history and pillability, then I am fine to move to oral treatments.

2. IV versus SC versus IM

We used to believe that Vit K took up to 48hrs to return PT and APTT to normal. However, the seed references promoting that belief do not stand up to modern scrutiny.

Recent studies suggest there may in fact be resolution of PT/APTT within the first few hours—for the IV route, the resolution can begin to be seen after the first hour.

That supposed quick resolution would explain why, despite transfusions being the Gold Standard for active haemorrhage in these baited patients, many vets in practice would not have commonly performed transfusions and yet did not lose patients.

Intravenous

I have yet to give such a baited case a transfusion, but have given the older brand injection IV in severe presentations and SC in those of less concern.

The lipophilic nature of pre 2021 Vit K₁ injection products makes SC injection with the smallest gauge needle in several sites a safe, effective alternative to the high-risk of anaphylaxis IV option (reserve for severest cases) or to the potential post injection muscle haemorrhage and necrosis of IM injections.

- To reduce the chance of an adverse drug reaction (ADR) to the lipophilic **Koagulon** injection when given IV, we pre-medicated with oral liquid Phenergan, gave the Koagulon injection slowly IV and followed up with an IV Dexamethasone dose. (I like using an anti-histamine co-drug as it calms most dogs, facilitating them to lie quietly in a padded box or kennel for the first few hours).

2021: The new injection product; **Konakion MM** formulation comes with the ability to be given IV with a lower risk of ADR as long as you do it slowly.

However, from my reading—even the MM formulation still has a risk of anaphylaxis.

There are 2 risk components to the delivery: *Dose/kg* and the *Dose/minute*.

- **Dose/kg**
Lower doses of 1mg/kg shown to be as effective as the higher 5mg/kg dose.
Dilute in 50mLs of fluid, and give slowly over 15-20 minutes to reduce the risk.
- **Dose/min**
Confusion reigns over the mg/min dose—anything from 0.5mg/min up to 10mg/min advised.

It is recommended to select the lower end dose of both.

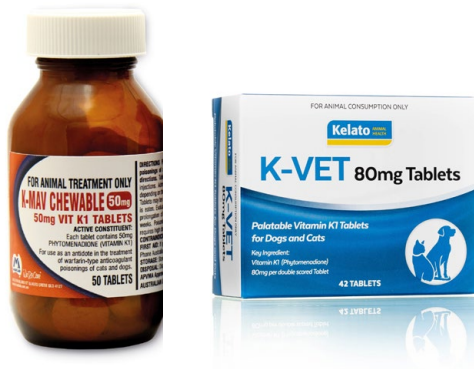The best advice is probably to monitor closely, stop at the first hint of any concern and administer anti-histamine or adrenaline as fits the given case ASAP.

SC Route

Despite the new opportunity to give an IV dose, there are some situations—individual dog's temperament, need for minimal restraint or no staff to assist (i.e. your vet staff suddenly Covid self-isolating for 5-14 days with zero notice) wherein you need the option of the SC route.

Stock Level Cost V Waste

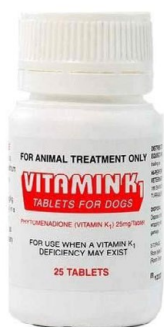Tablets



K-Mav 50mg Chew (A) x 50 Vs K-Vet 80mg tab (B) x 42

- Visual better on the K-Mav chew
- Palatability probably equivocal.
- Significant savings *currently* on the K-Vet product

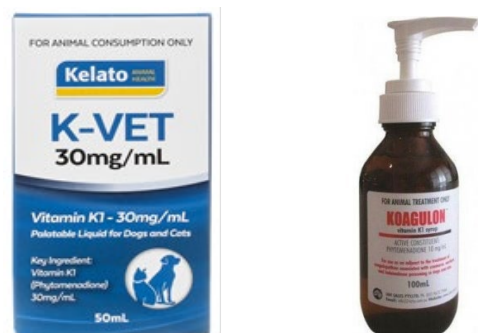K-Vet 80mg would be my tablet stock preference.



Ceva; Vit K1 25 mg x 25.

This third option with only 25 tablets and of lower strength works out financially handy for those practices that rarely see rodenticide poisonings, but still need to have some form of Vitamin K on the shelf for starter not maintenance use.

Liquid Formulations



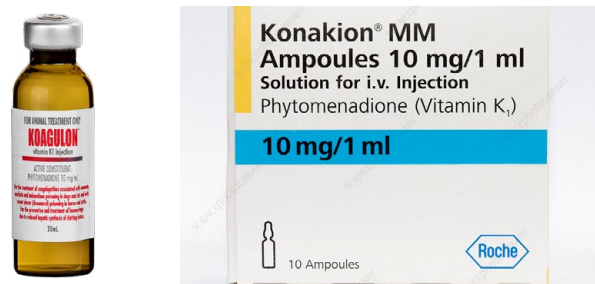K-Vet liquid Vs Koagulon Syrup

1. Both veterinary-specific products.
2. K-Vet has a significant 30% price save.

3. K-Vet has higher concentration/ml so less to be flung out.
4. K-Vet Very cleverly formulated to roughly correlate, at 2.5mg/Kg K1, to Meloxicam canine suspension volume doses. *K-Vet 30mg/ml would be my liquid shelf preference.*

Injections

Koagulon Injection V Konakion MM vials



- The Konakion vials offer a wider treatment option as safer IV as well as having SC use.
- Whilst comparing mg/mL-the cost/mg is more for the MM vials but the outlay purchase cost to have an injection option on hand is significantly less for the vials. That results in reduced financial outlay in wastage and removes any concerns over open breach dates versus expiry dates.
- Richard Malik has advised me that this MM formulation can also be used SC or intraperitoneally, thus making it an ideal product to have in our drug cupboard.

Konakion MM vials would be my injection shelf preference.

Semantics leading to Poisoning

In researching for this article, I was concerned to see the Konakion MM injection for IV use constantly referred to as a 'syrup'.

Given there are 2 other actual oral syrup preparations available—Koagulon and K-Vet-liquid, I am waiting for the day when we see the first report of iatrogenic ADR from the sole oral liquids being incorrectly injected IV.

To add to the confusion, there is a valid option to use *the reverse scenario*—the Konakion MM injections have a licence to be also given orally.

Is there an option for the Koagulon injection to be given orally? Perhaps so.

#Shortages and Upcycling: Plan B for unwanted Koagulon Injection

In the 2012 outbreak, demand outstripped supply, resulting in vets having to ration out a week supply at a time per patient, to trickle feed the need until

more product arrived into rural areas. Obviously, since Covid, the less one has to visit anywhere to get an order filled, the safer for all, so that 2012 solution is not so good a fit anymore.

However, I read an interesting article about the injectable versions, either straight or compounded, being effective when used orally for treatment.

'Based on the available literature, the administration of injectable vitamin K via oral route is effective and safe. Injectable vitamin K for oral administration can be prepared as an undiluted solution or as a compounded solution. These 2 formulations have different beyond-use dates depending on ingredients used. Information on efficacy and stability of injectable vitamin K formulations prepared for oral administration provides an additional option for health care systems when vitamin K tablets are unavailable or cost-prohibitive to use'.

This alternative use could prevent some unwanted Koagulon injection from going to waste.

Miscellaneous Points

- Secondary Relay toxicity.
All baits are not equal in their primary or secondary relay toxicity risk. Some authors claim it is impossible as a dog would need to eat half their body weight in poisoned rat to be affected. Perhaps for 1st Gen, but 2nd Gen relay poisoning is often seen in practice. Mount clearly shows that one rat poisoned by 100gm of bait (0.005% active ingredient) could well cause lethal poisoning in a 13.6kg dog. Given that close to 70% of cases in Haines' (6/2008 AVJ review of 252) cases were small to medium dogs, it is no surprise that general practitioners see this scenario not infrequently.
Richard Malik also shared with me, that one baited dead mouse is enough to cause death in any chicken or duck who ingests said mouse.
- A clinically unaffected Dam can have affected foetus/neonates, with both detectable levels of 2nd Gen and severe clinical signs in the litter
- Feeding with a fatty meal of tinned food increases Vit K₁ absorption 4-5 fold. However, Mineral oil reduces absorption.
- Individual animals can be clinically affected with a smaller dose of rat bait.

Toxin Generation 3 or Type Unknown or Inandione (Diphacinone) – JSAP 2021

Treatment of 2.5-5mg/kg SC then 2.5mg/kg PO divided every 8-12hrs for 3-4 weeks.

Test 2 days later and if PT elevated, therapy should be for 2 additional weeks.

If PT is not elevated then test again 48hrs later, then 1 week later.

If abnormal—continue for an additional week and recheck PT times as above.

Summary

At any time, be the presentation that of a valuable working dog, living often hours drive from a vet clinic or a beloved family pet in our area, *I personally can't risk that the first bait the owner saw was the first bait the dog ingested.*

(**Tip:** Always do a gentle faecal scoop as well—to look for melaena or pellet colour).

That lack of surety, of what/when the bait ingestion happened, means that the Gold Standard option of sending it back up the mountain road or just home locally to wait for 2-3 days to re-test to see if bait had been ingested, could be a time bomb waiting to happen.

Equally, the additional cost and travel inconvenience of regular on-going blood test monitoring is often not an option for many owners.

During the Covid pandemic combination of increased work, less staff available and the need to keep owners away where possible, the option to *treat not test* the asymptomatic comes into its own.

Therefore, my preference in 2021 is still to *treat, rather than monitor testing*:

- Injections will always be my starting point.
- IV injections would replace SC dependent on stage of presentation and animal temperament.
- Home dosing will be oral meds at the best cost-break for the client
- Treat for at least 42 days for 2nd gen.
- This 42-day **minimum** is safe, keeps the animal safe, *protects against potential catastrophic haemorrhage late in the equation* and so contains the overall emotional and financial impact on the client to the lower levels.

Keywords: vitamin K, phytonadione, injectable, oral administration, stability, compounding. ♦



References available in the eBook



Perspective 101, A Toxicologist's Perspective, Rhian B Cope & Rosalind Dalefield, Issue 273 Dec 2013

Small

SUBMANDIBULAR SWELLING POST METHIMAZOLE TREATMENT

Christopher Simpson

Victoria Veterinary Clinics

Hong Kong

simpson_christo@icloud.com

C&T No. 5912

A 15-year-old male neutered Domestic Shorthaired cat presented with a history of chronic vomiting and marked weight loss, previously having had a normal appetite. In the 24 hours prior to presentation, he had vomited many times and become inappetent.

He had been diagnosed with hyperthyroidism several months previously at another clinic, and at the owners' request, been managed with diet only (Hills y/d®). Diet compliance had been poor, as he frequently refused the prescription diet, and was offered other foods. As result, control of the hyperthyroidism was considered inadequate.

He had also previously tested positive for FeLV.

On physical examination his body condition score was 3/9, and he had a grade 2/6 systolic heart murmur.

Haematology and biochemistry were performed as well as proBNP, chest radiographs and echocardiography.

Blood tests revealed a mild non-regenerative anaemia, elevated liver enzyme activities with concentrated urine (USG>1.050) and an abnormal proBNP. A repeat in-house FeLV test (SNAP FIV/FeLV Combo®) was positive but notably, a subsequent PCR test was negative.

His total T4 concentration was 160 nmol/L (reference interval 9.5–48 nmol/L).

Blood pressure measurements could not be obtained, as the cat was too aggressive. Fundic exam was normal, without any features suggestive of current or previous hypertensive retinopathy. Vision was subjectively normal.

A prominent mobile left-sided thyroid nodule was palpable.

Chest and abdominal radiographs revealed mild cardiomegaly with a valentine-shaped cardiac silhouette and a small amount of mineral opacity within the kidneys bilaterally.

Echocardiography showed moderate left ventricular hypertrophy and left atrial enlargement, while abdominal ultrasound examination found bilateral adrenomegaly, slightly increased splenic thickness and mild diffuse thickening of the jejunum.

All the abnormal findings were considered most likely to be attributable to the hyperthyroidism. FeLV antigenaemia was confirmed but there was no other evidence of progressive infection at that time.

The cat was started on methimazole 2.5mg/0.05mL transdermally twice daily and maropitant 1mg/kg once daily plus mirtazapine 0.05mL transdermally once daily.

One week later, his owner reported that he was more settled with a good appetite and no further vomiting. However, on physical examination he had marked submandibular swellings.

Ultrasound examination confirmed abnormal tissue which had a firm rubbery consistency, but which was acellular/non-exfoliative on attempted FNA.

His total T4 concentration had decreased to 47 nmol/L.

Possible Adverse Drug Reaction

The submandibular swelling occurred very quickly after methimazole treatment suggesting the possibility of an adverse drug reaction (ADR) to the drug.

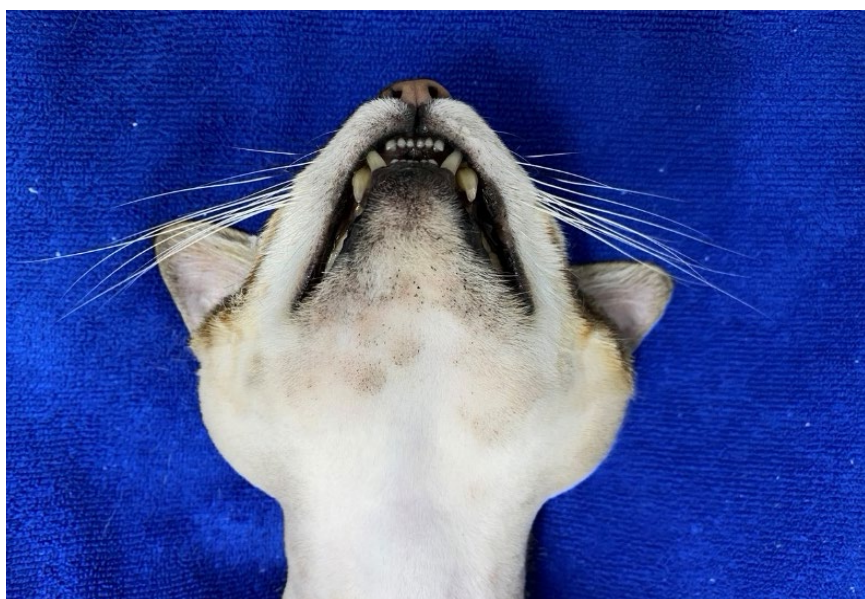


Figure 1. Ventral aspect of the cervical and cranial region of the cat during methimazole therapy

Carbimazole or methimazole are considered the agents of choice when using drugs to treat feline hyperthyroidism. Carbimazole is a pro-drug of methimazole, and is metabolised to methimazole, so in general, any ADR to one drug is most commonly observed with the other.

Well recognised ADRs to carbimazole and/or methimazole

Include:

– Self-induced facial excoriations	2.3%
– Bleeding	2.3%
– Hepatopathy	1.5%
– Thrombocytopenia	2.7%
– Agranulocytosis	1.5%
– Positive direct antiglobulin test	1.9%

Rarely myasthenia gravis has also been reported. These effects generally necessitate withdrawal of the drug and switching between methimazole and carbimazole is unlikely to be useful for the reasons above.

Occasionally gastrointestinal (GI) side-effects may be observed with oral carbimazole, and since these may in some cases be related to the bitter taste of the medication, transdermal methimazole may improve clinical outcomes in such cases.

A less common ADR to methimazole

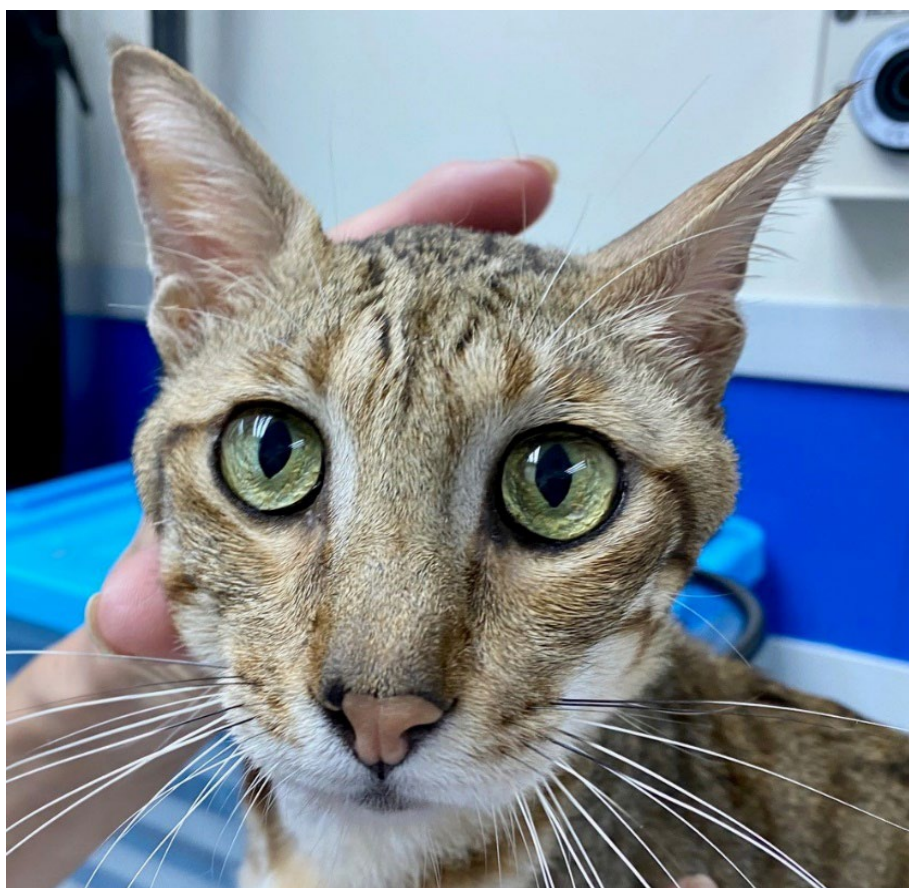Less common, but previously reported, is mandibular lymphadenopathy. This has been described in Snead *et al* *CWJ* 2013—*Cutaneous*

lymphoid hyperplasia mimicking cutaneous lymphoma in a hyperthyroid cat. In this case, treatment with methimazole was rapidly followed by marked swelling of the facial skin and enlargement of the mandibular lymph nodes. As the title of the paper suggests, histologically the lymph node changes mimicked lymphoma, but the changes regressed rapidly upon withdrawal of methimazole, and *did not recur* when treatment was reinstated with oral carbimazole. The mechanism behind this unusual phenomenon is not understood.

With this in mind, we pursued the same strategy in our case. Upon withdrawal of methimazole, the cutaneous and submandibular changes regressed over a period of 3 weeks. At this time, overt and severe signs of hyperthyroidism recurred, and treatment was recommenced with oral carbimazole. Fortunately, this resulted in rapid and effective control of the hyperthyroidism, without recurrence of the other adverse effects. The cat remains well at the time of writing.

We report this case to alert clinicians to the uncommon occurrence of mandibular lymphadenopathy as an ADR to methimazole, and the potential to manage such patients effectively with carbimazole as an alternative in such cases. ♦

Figure 2: Appearance of the cat's head face on



Small

ANSWER TO 'WHAT IS YOUR DIAGNOSIS?' C&T NO. 5898

SUBLINGUAL LESION IN A CAT

Hannah Wilson DVM4 Vet student

hwil6702@uni.sydney.edu.au

Randolph Baral BVSc MANZVSC
(feline) PhD

Paddington Cat Hospital

210 Oxford St

Paddington NSW 2021

+612 9380 6111

C&T No. 5913

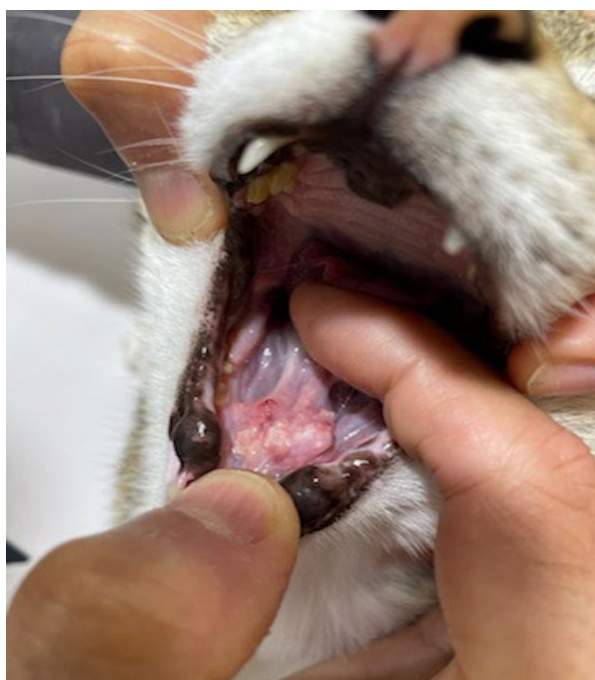


Figure 1. Appearance of sublingual mass at presentation

History

An 11-year-old male neutered Abyssinian cross was presented for hyporexia of two days duration; the cat would go to the food bowl, take a few nibbles, and then stop which was different to this cat's typical enthusiastic eating.

On examination, a 2 cm irregular lesion was recognised rostrally, under the tongue: the lesion was a similar colour to surrounding mucosa with focal creamy-white nodules (Figure 1).

The cat's chin was mildly swollen.

The body condition score was a 5/9 and a loss of 220 g in body weight was noted from the visit one month prior. There was evidence of dental disease on oral examination. The heart sounds were normal, and the rate was 200 bpm.

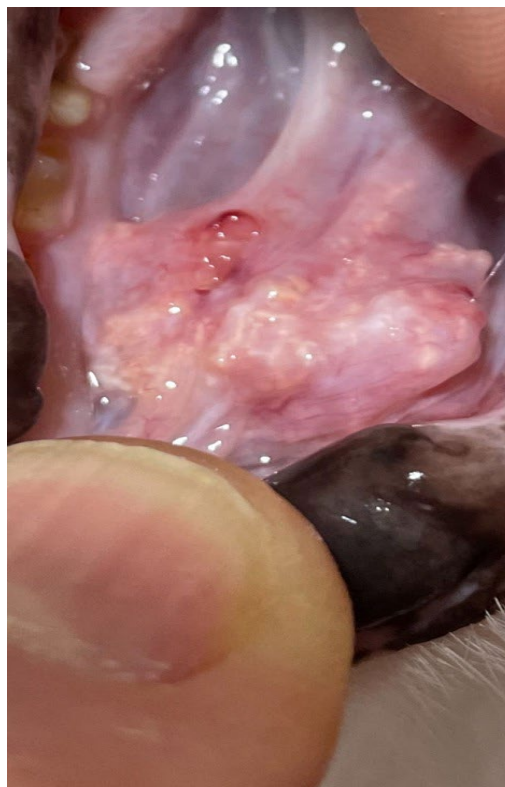


Figure 2. Close up of the sublingual lesion

Questions

What diagnostic tests could be considered?

Differential diagnosis considered in this case were neoplasia, eosinophilic granuloma complex, sialocoele, soft tissue trauma, foreign body, and viral infection. Complete blood count, serum biochemistry, and urinalysis were all unremarkable. Dental radiography, computed tomography and tissue biopsy could additionally be helpful to rule out the potential cause(s) of disease. In this case, the cat was admitted to biopsy the lesion.

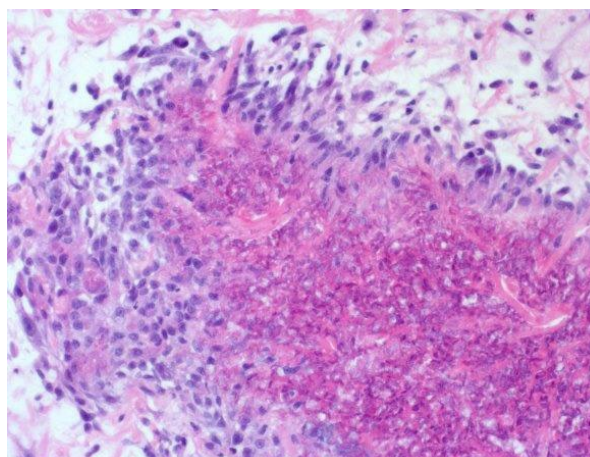


Figure 3. Flame figures representing amorphous eosinophilic debris.

What is your diagnosis?

Biopsy results revealed hypereosinophilic granular material with noted flame figures present (Figure 3), which is characteristic of eosinophilic granuloma. This is part of the feline eosinophilic granuloma complex (EGC), which consists of three separate but similar diagnoses—indolent (or eosinophilic) ulcers, eosinophilic plaques, and eosinophilic granulomas.

Ulcers are normally found on the upper lip and do not normally cause pain or pruritus. Eosinophilic plaques are characterized by intense pruritus but appear on the belly and thighs more commonly than the lip. **Eosinophilic granulomas can be seen anywhere on the body but are most often found on the dorsal surface of the tongue and hard palate** (Ehlers *et al.*, 2019).

EGC is commonly seen with allergic skin diseases in cats, such as flea bite hypersensitivity, cutaneous adverse food reaction and atopic dermatitis. It is therefore common to see clinical signs associated with feline allergic disease concurrently with EGC lesions, such as miliary dermatitis, head and neck pruritus or symmetrical alopecia (Buckley & Nuttall, 2012). **In the case of this cat, previous history showed similar lesions of this nature as well as lesions of the lip and tongue. However, this cat differed from the expected presentation, as the eosinophilic lesion existed on the sublingual surface, rather than on the dorsal surface of the tongue.**

While awaiting the results of the biopsy in this case, the cat re-presented one week later with alopecic lesions attributable to overgrooming stemming from pruritis. The areas of alopecia were located between the shoulder blades, measuring approximately 1-1.5 cm and 3 cm in diameter and were erythematous in nature. A smaller lesion cranial to left hind limb was also noted.

The cat was started on prednisolone (5mg per day for 10 days then every second day until finished).

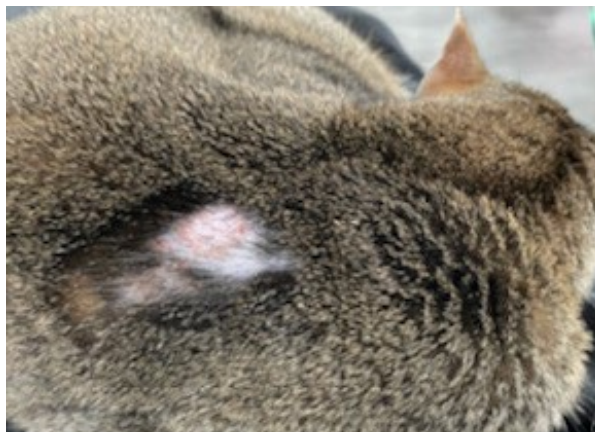


Figure 4. Dermal lesions

The dose was subsequently increased to 10mg per day after the biopsy revealed the lesion was an eosinophilic granuloma.

What further diagnostic tests could be considered?

Upon initial presentation of suspected EGC lesion(s), skin scrapings, trichogram, and/or skin cytology are good places to begin with diagnostics. Parasites, especially fleas, are often associated with EGC as they trigger an allergic response. If the presence of pruritus cannot be confirmed, a trichogram can be used to reveal broken hair tips, which would indicate itchiness if found. Skin cytology is especially helpful for identifying bacterial and yeast infections and a fungal culture can help to rule out dermatophytosis. Once EGC is suspected as the cause of the lesion, a definitive diagnosis can be made through fine needle aspirate (FNA) or biopsy (Foster, 2003; 'Oozing Tumor-Like Bumps: What's behind eosinophilic granuloma complex?', note Catwatch, 2021). Alongside investigations into EGC lesions, thorough history taking should be undertaken to reveal potential inciting cause(s) of the allergy.

What is this cat's prognosis?

The prognosis is good with treatment and identification of underlying disease. Eosinophilic granulomas can require higher than normal doses of glucocorticoids and some cases can even be refractory to treatment. Adjunctive therapies should be considered if insufficient or no response to treatment is noted or if the underlying cause of disease remains uncertain.

Cyclosporin has been advocated as a potential alternative therapy for the treatment of EGC in cats, especially in those cats whose lesions remained after administration of glucocorticoids (Vercelli, Raviri, & Cornegliani, 2006). One study investigated the efficacy of a 0.054% hydrocortisone aceponate (HCA) spray for treatment of presumed feline allergic skin

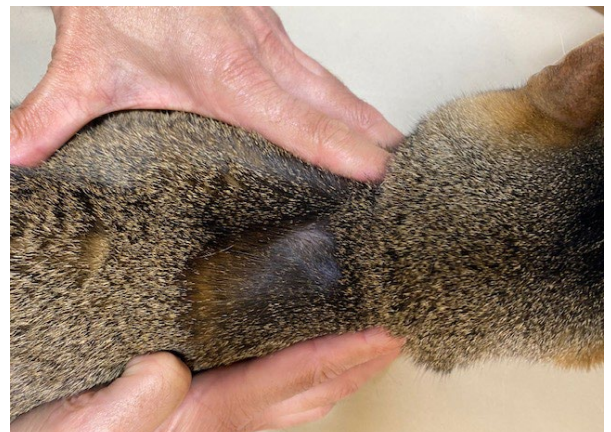

Figure 5. Healing alopecic lesion on dorsum

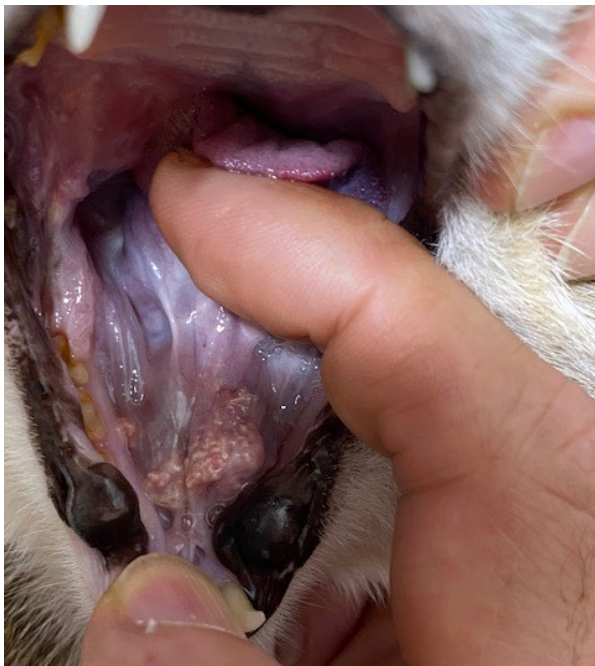

Figure 6. Resolving sublingual eosinophilic granuloma lesion.

disease, which suggested that the treatment was efficacious, but acknowledged the need for further studies into HCA as a treatment option.

Chlorambucil is not licensed for use in animal species but is commonly used in feline medicine and the drug is considered safe. It has been considered as a treatment in EGC cases that were unresponsive to steroid treatment (Buckley & Nuttall, 2012).

Long-term control of allergic disease can be managed through the elimination of allergic triggers, such as good flea control, diet alterations, or environmental changes to reduce exposure to allergens. Antihistamines, fatty acids and palmitoyl ethanolamide have been found to have some efficacy in controlling allergic skin disease as well (Mueller, Nuttall, Prost, Schulz, & Bizikova, 2021; Scott & Miller, 1999).

In the case of this cat, Comfortis™ (spinosad) was used for flea control, having a speed of kill of half an hour; this made flea bite hypersensitivity unlikely. Environmental allergens could be suspected in the case, as the cat had access to outdoors and no diet trials were undertaken, so food allergy cannot be ruled out as the inciting cause of the allergic process. Further investigation will be needed to ascertain this cat's allergic trigger(s). The alopecic lesions on the dorsum began to heal with administration of the 5mg sid prednisolone dose after a few days (Figure 5). Treatment of the sublingual lesion continued with the 10mg sid dose of prednisolone and showed marked improvement at recheck approximately 1 month after initial presentation (Figure 6). The

lesion was entirely resolved after 6 weeks of 10mg sid of prednisolone, at which time the dose was tapered to 5mg daily. Since excellent flea control was already in place (Comfortis monthly), a food trial with goat meat was started.

When prednisolone was further tapered to 5mg every second day, the owners recognised that the cat started to lick at himself again. Blood was drawn for serum ALLERCEPT® Allergy IgE testing that showed a moderately strong positive result for *Tyrophagus putrescentiae*. *T. putrescentiae* is a storage mite that is often found in cereal grains. Allergy to storage mites in small animals is typically associated with dry food. This cat's diet was entirely wet food but discussions with the owner about possible exposure revealed that the cat would lick clean the owners' cereal bowls each morning. With the possibility of storage mites in the owners' breakfast cereal, the owners stopped offering their cereal bowls and the lesion entirely resolved (the cat was so well that he would not allow a photo) and prednisolone was able to be discontinued. Some months later, the cat started licking himself again and the owners admitted that they had gone back to their habit of offering their finished cereal bowls. When they again stopped offering this, the pruritis again resolved.

References

- Buckley, L., & Nuttall, T. (2012). Feline Eosinophilic Granuloma Complex (ITIES): Some clinical clarification. *Journal of Feline Medicine and Surgery*, 14(7), 471-481. doi:10.1177/1098612x12451549
- Ehlers, L. P., Slaviero, M., Piccolo Vargas, T., Argenta, F. F., Driemeier, D., Amorim da Costa, F. V., Sonne, L. (2019). Epidemiologic and Pathologic Aspects of Feline Eosinophilic Granuloma Complex. *Acta scientiae veterinariae*, 47(1). doi:10.22456/1679-9216.98316
- Foster, A. (2003). Clinical approach to feline eosinophilic granuloma complex. *In practice* (London 1979), 25(1), 2-9. doi:10.1136/inpract.25.1.2
- Mueller, R. S., Nuttall, T., Prost, C., Schulz, B., & Bizikova, P. (2021). Treatment of the feline atopic syndrome – a systematic review. *Veterinary dermatology*, 32(1), 43-e48. doi:10.1111/vde.12933
- Catwatch. (2021). Oozing Tumor-Like Bumps: What's behind eosinophilic granuloma complex? Feline Health Center, Cornell College of Veterinary Medicine, 25(5), 4. protect-au.mimecast.com/s/wunVC6XQ4LfrYGQNOfp3lrS?domain=catwatchnewsletter.com
- Scott, D. W., & Miller, W. H. (1999). Antihistamines in the management of allergic pruritus in dogs and cats. *Journal of Small Animal Practice*, 40(8), 359-364. doi:10.1111/j.1748-5827.1999.tb03099.x
- Vercelli, A., Raviri, G., & Cornegliani, L. (2006). The use of oral cyclosporin to treat feline dermatoses: a retrospective analysis of 23 cases. *Veterinary dermatology*, 17(3), 201-206. doi:10.1111/j.1365-3164.2006.00514.x

AND A SIMILAR ANSWER TO WIYD? C&T NO. 5898

Pete Coleshaw

Jaffa's Health Centre for Cats

Salisbury, United Kingdom

jaffa@jaffavets.com

My case of sublingual EGC involved a 7-year-old Russian Blue cat, Teddy. The lesion presented with typical white-ish areas. A quick impression smear stained with Diff-Quik confirmed our thoughts, which were backed up by histopathology confirming 'Eosinophilic granuloma complex, with ulceration and flame figure formation'.

Initially, due to tableting issues, treatment was a 0.2mL loading dose of dexamethasone plus 0.3mL depomedrone to follow on. The initial response was favourable with the lump shrinking to a quarter of its initial size before returning with a vengeance despite 2 further doses of Depomed.

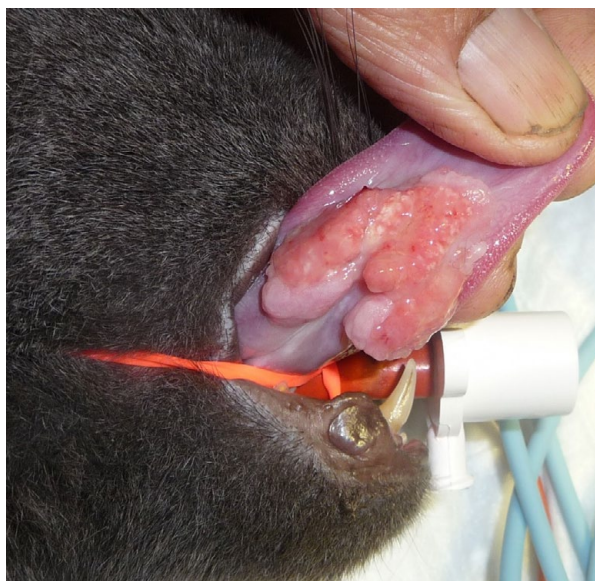

Figure 1. EGC lesion near the lingual frenulum on the ventral surface of the tongue

Most of you will be far too young to know about Ovarid (Megestrol acetate) which was marketed very heavily 30 or more years ago as a treatment for EGC in addition to its primary use for contraception. It worked very well, though it did tend to make them big, fat, and lazy if used excessively—and occasionally diabetic.

Having run out of my long out-of-date Ovarid tablets and facing likely compliance issues with Atopica, the next step was delvosterone injection (1mL) along with a single-source protein diet. The cat/client interface failed with both diet and Delvo. I read around and found different (historical)

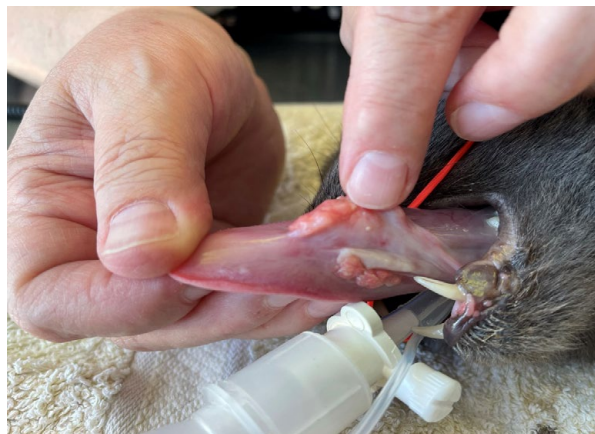

Figure 2. Back with a vengeance

regimes discussed and then upped the dose of delvosterone to 2.5mL one month after the initial dose. Disappointingly, this also failed to achieve the correct result. It did however create polydipsia and lethargy which was left to sort itself as the drug wore off. We did not see him for a while then, as I think the owner shared my concern of the pill being worse than the disease.

My medication of last resort is Depo-Provera, but there is precious little information about doses and side effects in cats although both can be extrapolated—and whilst my mantra is that the risk of side effects is always preferable to euthanasia, I had serious concerns about the potential development of diabetes—and I did not feel we were quite at 'last-ditch' stage.

By the time we saw him again the lump had returned with a vengeance causing a lot of oral discomfort and it was time to push the compliance side—have you ever noticed how compliance can be achieved when the options start running out?

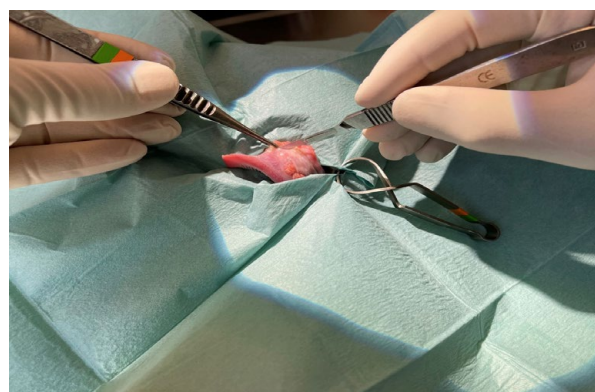
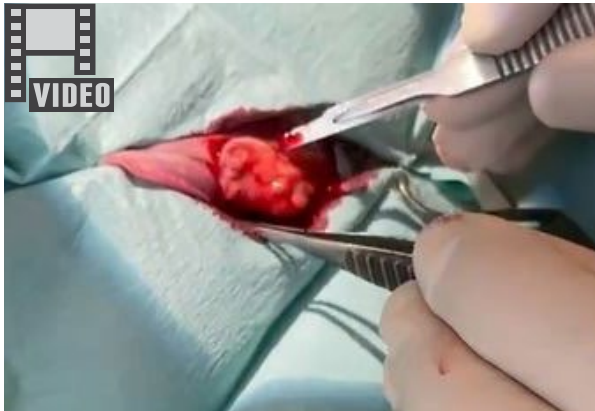

Figure 3. Surgery – wasn't that hard after all!

Teddy's dad is a hunter, so we got in a good supply of venison (suitably meat-inspected!) and he was successfully enticed onto a raw diet. Despite reservations, he also took the prescribed cyclosporine satisfactorily. I often find they will accept Atopica for 10 days or so before deciding it is not for them anymore. However, after 3 weeks there was little change. Richard Malik suggested



Well, it was actually quite simple, straightforward, with minimal ooze—which is why I felt motivated to write this piece. Do consider surgery as it is not as scary as you would think—the one side with the biggest lump took less than 5 minutes! You can see my video of this—forgive the hopeless quality as my camera person was too far away and I had to zoom the footage—but you can see the principle.

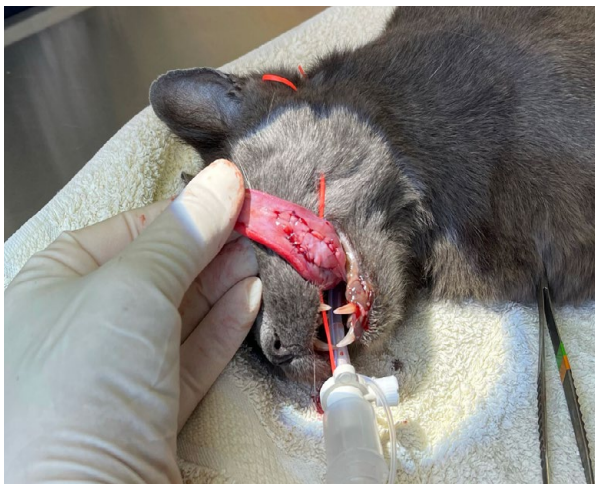

Figure 4. The finished job

surgical obliteration and we scheduled Teddy for this, subsequent to a hoped-for reduction in size.

The diet/Atopica combo worked well over the next couple of weeks with the large bilateral mass shrinking to one smaller solid mass on one side, with several small satellite masses on the other.

So, we then had a dilemma—do we medicate to conclusion and expect to throw immuno-suppressives at him long term, (few ECG lesions

stay in remission unless dietary, in my experience) or do we excise now that surgery looks possible? We chose the surgical route—but by the time the cat was on the table (and we were fully able to inspect the lesions) the huge improvement did make me reconsider the continued conservative approach. However, the cat was under general anaesthetic—let's get the job sorted!

Whilst tongues heal very rapidly, presumably due to their excellent blood supply, that same blood supply is always in my head—surely excision will create a blood bath!

Further thoughts: my margins included tissue that was previously covered by ECG tissue—is this ready to rebound when the immunosuppressives cease? Should I have waited and seen if all healed without surgery? Who knows! But by giving it a go I learned. I moved outside my comfort zone.

Getting philosophical in my old age, I worry that the veterinary profession has become disempowered, fearful of litigation, afraid to try things in case it goes wrong. So much of what we believe or have been taught has so little evidential base.

What is my take home message?

Well, read around your challenging cases, discuss with open-minded colleagues, establish the pros and cons, make an informed evaluation, and discuss the issues with your client. Record your discussions—most clients will appreciate your concern and you will quickly find out who is not on board. Informed consent covers you legally. You will have failures—and rampant successes.

My latest success is an 18-year-old ataxic cat that is responding in an amazing manner to oral GS-44 (Mutian tablets) treating its cerebral FIP. It makes the whole vet-thing so worthwhile. If you are getting jaded let me reassure you the cases are out there to heal—and to enjoy —so go for it!! But if you do not seek you will not find! ♦



TimeOnline OnDemand Start now!

Self-Paced Learning Gives YOU Control & Flexibility | 5 CPD points

Cost: \$150 for all Members, \$300 for Non-Members

Small Animal Dentistry TOL OnDemand (Vets)

Tutors: **Tony Caiafa & Kayo Kuroda**

Canine Aggression: Approach & Management TOL OnDemand (Vets)

Tutor: **Sally Nixon**

For full list of courses visit: cve.edu.au/timeonline-ondemand

Winner

Entitled to a CVE\$100 voucher

Small

FELINE LUNGWORM (*AELUROSTRONGYLUS ABSTRUSUS*) INFECTION IN A KITTEN

Ben Mills BVetBio/BVSc (Hons I)

Southern Beaches Vet Clinic

Dodges Ferry, Tasmania

benjamin@sbvet.com.au

C&T No. 5914

To briefly set the scene, this was my first cat anaesthetic/surgery as a veterinarian, having only graduated weeks prior. I hope for all future new-graduates that your experience is a little less stressful than mine and that for your first anaesthetic emergency, you have a team as experienced and supportive as I did, to help you work through it.

Background

Mochi, an approximately 12-week-old, female entire DSH kitten presented to Southern Beaches Vet Clinic for ovariohysterectomy. She was a stray kitten found on her owner's farm, living with one dog and had an indoors/outdoors lifestyle.

Mochi had first presented one month prior to this visit for a check-over and first vaccination, it was noted in her history that she coughed approximately once per night, she had also been

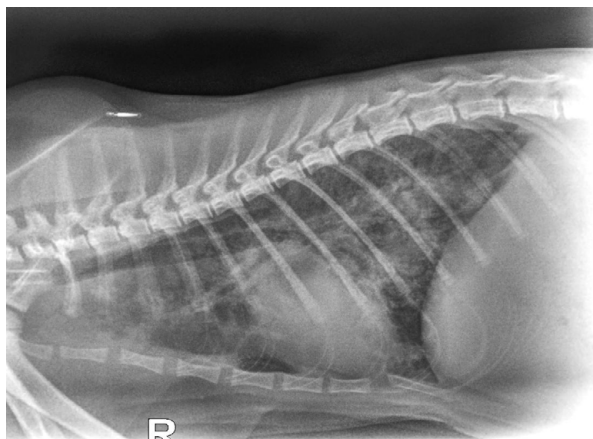

Figure 1. Right lateral thoracic radiograph showing a moderate-marked mixed bronchoalveolar pattern

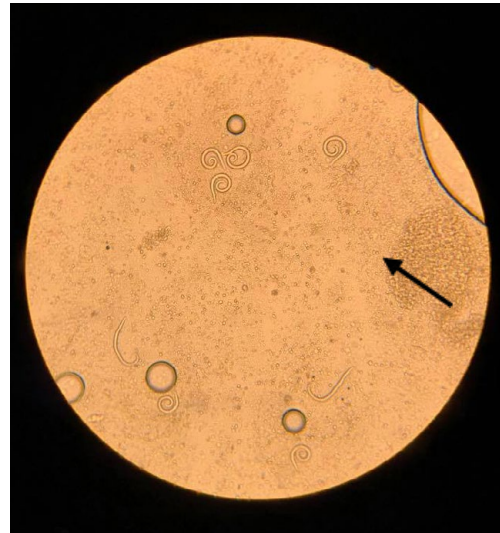

Figure 2A. 10x magnification showing 9 L1 larvae – all were highly motile. A cluster of 3 larvae is denoted by a black arrow.

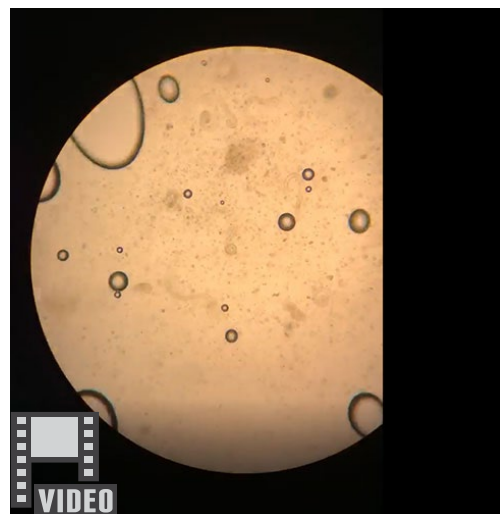


Figure 2B. Watch the video.

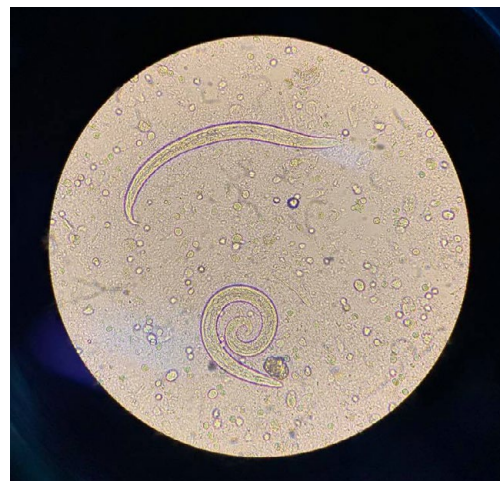

Figure 3. 20x magnification showing internal structure of lungworm L1 larvae.

dewormed by the owner; however, they were unsure of the product/dose used.

On pre-anaesthetic examination, Mochi was clinically normal with normal/clear breath sounds across all lung fields, no coughing, and a respiratory rate of 68 breaths per minute (BPM). Mochi was sedated with

0.01mg/kg acepromazine and 0.3mg/kg methadone IM, sedation was mild but allowed for intravenous catheterisation. Anaesthesia was induced with alfaxalone IV, slowly to effect, and a 3.0mm ET tube was placed.

Anaesthetic emergency

Immediately after intubation, Mochi's respiration began to sound harsh and raspy across all lung fields. This quickly progressed within minutes from being audible with a stethoscope to being audible from metres away. Heart rate and SpO₂ remained normal. A lateral thoracic radiograph revealed diffuse, severe pulmonary effusion and thickening of the bronchial walls; the cardiac silhouette was difficult to assess due to border effacement with the fluid filled lungs (Figure 1).

Terbutaline (0.01 mg/kg) was administered IV and the isoflurane turned off 10 minutes later. Mochi recovered smoothly from the anaesthesia with flow-by oxygen provided, followed by being moved to a warmed oxygen cage. The breath sounds were greatly reduced once extubated, although still slightly harsh compared to the pre-sedation examination. Mochi was monitored closely throughout recovery and remained stable.

Diagnosis

On extubation, a large clump of mucopurulent material was noted on the distal end of the ET tube. A wet preparation examined under 10–20x magnification revealed many (> 100) motile L1 larvae (Figures 2 and 3). A Diff-Quik stained smear of the material showed a predominance of non-degenerate neutrophils, low numbers of eosinophils and macrophages. Cocci and rods were present, but no intracellular bacteria were seen. Based on these findings, Mochi was diagnosed with a severe *Aelurostrongylus abstrusus* (lungworm) infection with diffuse secondary bacterial pneumonia.

Adult feline lungworms (*Aelurostrongylus abstrusus*) live in the lung parenchyma, eggs hatch in the lungs and the L1 larvae move up the trachea, are coughed up and swallowed, before being passed in the faeces. Once in the environment, they are ingested by intermediate hosts (snails), which in turn can be eaten by various transport hosts including mice, rats, birds, reptiles, and amphibians.

Cats are the definitive final host, becoming infected when they ingest the intermediate or transport hosts, and the larvae migrate back to the lungs. It is generally considered that cats are much more likely to be infected by eating mice, frogs and lizards, because all experimental infections in which cats have been fed snails or slugs has

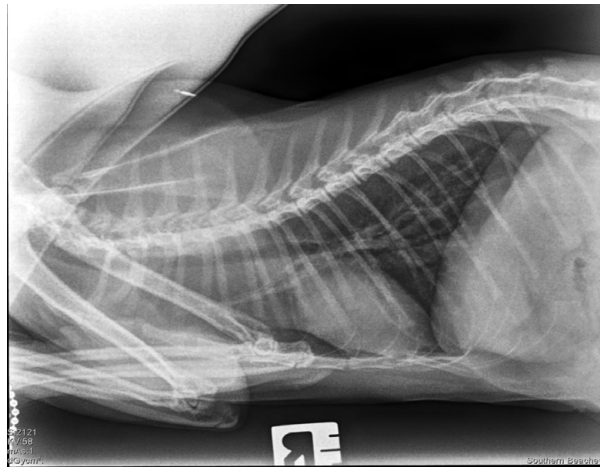


Figure 4: 10-week Right lateral follow-up thoracic radiograph.

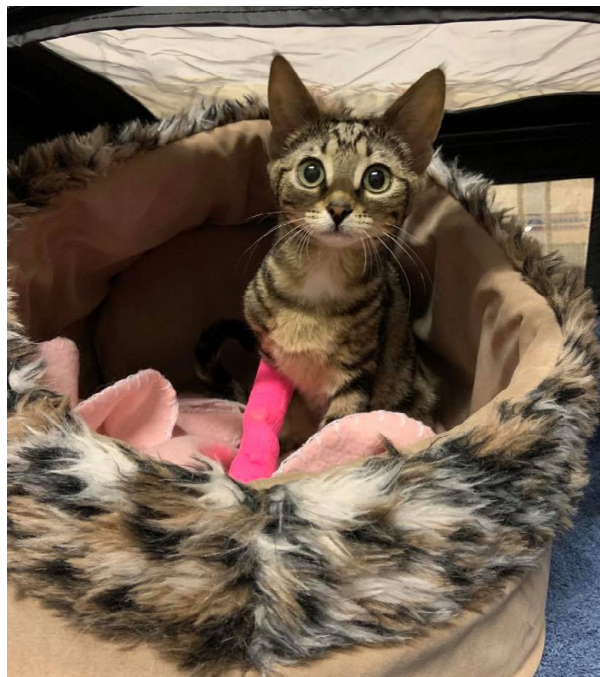

Figure 5: Mochi—a happy cat at the end of the treatment regimen.

resulted in immediate vomiting. The pre-patent period is 6 weeks, and adults may live in the lungs for up to 9 months. Most infections are said to be mild and asymptomatic, as in this case; however, severe infections can cause chronic cough, progressive dyspnoea, weight loss and even death.

For more information, see a terrific recent review and research study

Raue K, Raue J, Hauck D, *et al.* Do All Roads Lead to Rome? The Potential of Different Approaches to Diagnose *Aelurostrongylus abstrusus* Infection in Cats. *Pathogens*. 2021; 10(5):602. Published 2021 May 14. Doi:10.3390/pathogens10050602

Treatment

Following recovery from anaesthesia, Initial treatment consisted of 0.1mg/kg dexamethasone sodium phosphate IV, doxycycline 12.5mg/kg (for ease of dosing) PO with food once a day and

50mg/kg fenbendazole PO for 9 days. Throughout the afternoon, Mochi's respiration remained slightly raspy on auscultation, with respiratory rate ranging between 60 and 96, and slightly increased effort. The first 24–48 hours of treatment was the critical period as clinical status can worsen with inflammation due to the death of the worms within the pulmonary parenchyma. Mochi was hospitalised overnight for monitoring and remained stable.

It was advised that Mochi remain in hospital for a further 24–48 hours monitoring; however, this was declined by the owner due to financial constraints. Mochi was discharged the following day with the following treatment plan:

- Prednisolone 1.25mg/kg PO once daily for 9 days, then every other day for 8 days, then every third day for 6 days.
- Fenbendazole 50mg/kg PO once daily for 9 days.
- Doxycycline 12.5mg/kg PO once daily for 9 days.
- Keep indoors to break the lifecycle of eating mice, frogs, lizards etc. and consider FIV/FeLV testing in the future.

Other treatment options included moxidectin, selamectin or ivermectin. Many people currently think emodepside (Profender) may be the drug of choice. Fenbendazole was used as it was the cheapest option available and the client was cost constrained.

Outcome

Ten weeks after initial presentation, Mochi returned for repeat thoracic radiographs and ovariohysterectomy pending normal radiographic findings. According to the owner, Mochi received the full course of medications prescribed and no coughing had been noted in the weeks leading up to follow-up visit.

The follow-up lateral radiograph showed no abnormal findings, specifically, no discernible bronchoalveolar pattern as previously seen (Figure 4). Mochi was anaesthetised and spayed without complication and has since been healthy and well, living on the farm in South-Eastern Tasmania.

Acknowledgements

I would like to acknowledge the support of my team at Southern Beaches Vet Clinic, specifically my colleagues Dr Nerida Warburg and Dr Melinda Salter, throughout this difficult case. Also, a huge thank you to my university feline medicine lecturer Dr Ali Montgomery and Dr Richard Malik for their help with formulating a treatment plan for Mochi. ♦

IN-HOUSE BAERMANN TEST

Jan Slapeta

Professor of Veterinary and Molecular Parasitology

Sydney School of Veterinary Science

jan.slapeta@sydney.edu.au

C&T No. 5915

I teach all DVM students to make a funnel out of a PET bottle—cut the top third off, turn the top upside down and insert it into the bottom 2/3rds with a party balloon occluding the opening to collect the larvae. Faeces are placed on gauze and immersed in water in the inverted top section; there is a paper on this:

scielo.br/j/mioc/a/9p3KdJhSs4fhhnSMhwqKgmz/?lang=en&format=pdf




Figure 1. In-house Baermann using plastic bottle

There are other ways: scielo.br/j/mioc/a/hVyRsDwWHtwxs83ZmF7cTj/?format=pdf&lang=en

But the simplest is a method called Vajda

Warm a watchglass with luke-warm water, then place 2–3G of cat poop in gauze, roll into a ball (like a money bag) and place into the water in the watchglass; wait for 30min to 1h; remove the money bag and place the watchglass under the microscope the L1 will be there.



Figure 2. Vajda method

Editor's note: Diagnosis of rat lungworm—diagnostic delay because we are always in a rush

I have diagnosed many RATS with rat lungworm (*Angiostrongylus cantonensis*)—in a research capacity at Westmead, using Baermann funnel and the expertise of Rogan Lee, a vet who became a medical parasitologist. It's easy—if you have the gear. You can find motile L1 in rat faecal pellets in just a few minutes. It's a doddle.

I have never diagnosed CATS with lungworm (*Aleurostrongylus abstrusus*) using Baermann, but I have diagnosed lots of cases. In all instances, I looked at the cat, looked at the radiographs—thought the patient had asthma or bronchitis—and did a BAL/deep bronchial washing. And invariably, Trish Martin the cytologist, would happily tell me there were tons of L1 larvae, eosinophils, and often some translocated enteric bacteria on culture. I am aware of several cases diagnosed by George Reppas at Vetnostics where L1 were seen in fine needle aspirate biopsy of lung. That's OVERKILL!

Why?

BECAUSE I WAS ALWAYS IN A RUSH, and I never had cat lungworm at the top of my DDx. This little article by vet parasitologist Jan Slapeta shows a couple of nifty ways to diagnose lungworm in cats with home-made apparatus. IT JUST TAKES A LITTLE TIME.

Overseas, it is possible to make the diagnosis using PCR using a pharyngeal swab, but none of the commercial labs in Australia have offered this test. There is also a serological test using serum available in Europe.

But none of these tests is as sensitive and specific as a Baermann test for larvae on faeces as shown in this article.

So, the next time you have a coughing cat, ESPECIALLY A KITTEN, this is a test you can do BEFORE you do the BAL or transthoracic FNA!!!! Cost effective and very satisfying. The owners love seeing the larvae! It's also good to know in advance, as you should not treat them just with anthelmintics, as the sudden release of metazoan antigen can make them worse, judicious use of corticosteroids is very helpful, and with antimicrobial cover for enteric bacteria such as *Salmonella* and *E coli*.

Finally, another tip

In most cases fenbendazole or one of the macrocyclic lactones (ivermectin, selamectin, milbemycin, moxidectin) will clear the infection, but in severe infections ESPECIALLY in kittens, Profender containing emodepside is probably the drug of choice according to Jan. Always treat them a few times with different products. To prevent infections, choose a regular anthelmintic that covers cat lungworm.

Last item—cats get lungworm by eating transport hosts like mice, not by eating snails and slugs. Cats vomit up snails!

ANOTHER VARIATION OF THE IN-HOUSE BAERMANN TEST COURTESY OF

Liz Smit

squizardo@gmail.com

I work in a feline shelter in Northern Tasmania, Just Cats Tasmania.

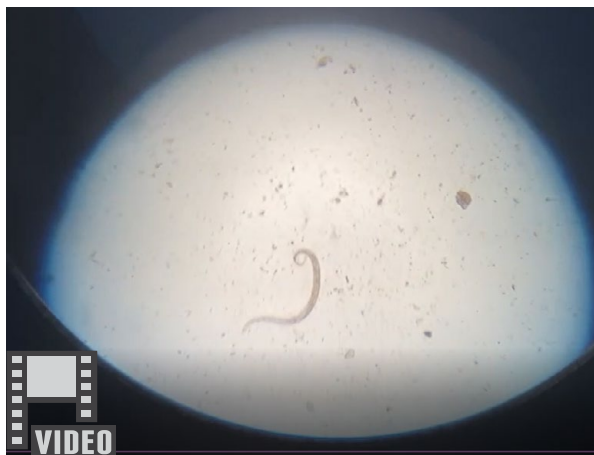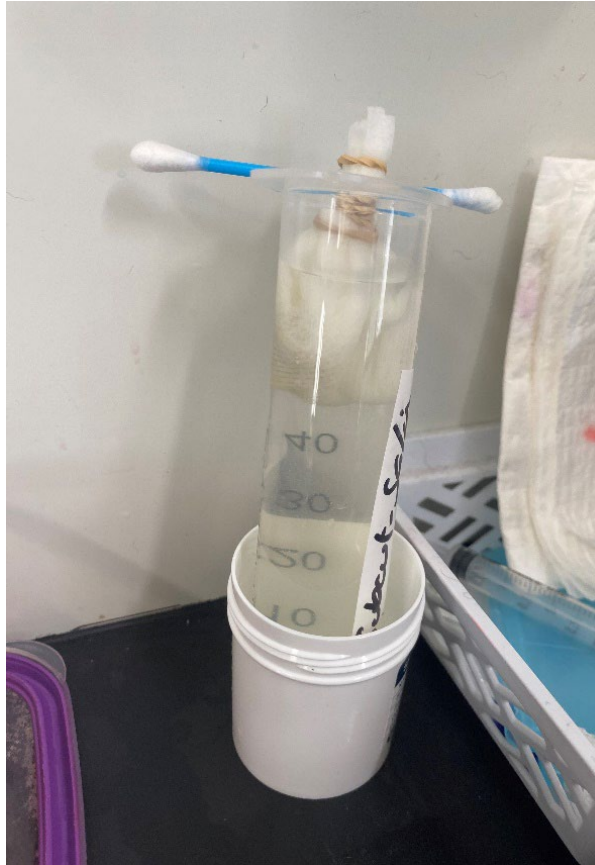
It is not uncommon to see otherwise healthy kittens in for routine neutering that have respiratory difficulty (increased respiratory effort) when put under general anaesthesia. (They will have had routine flea and worming treatment previously—either moxidectin based products or more recently selamectin.)

We currently do not have Xray facilities in our vet unit—and it has been frustrating to not have a definitive diagnosis—they are just assumed to have lungworm.

After consultation with Richard Malik, who also shared Jan Slapeta's findings, I decided to start testing using a 'practical in-house Baermann protocol.'

One of the articles Richard sent me used a plastic wineglass with a hollow stem. I hadn't yet managed

to acquire the wineglass—so I used a 60mL syringe—but otherwise the faecal sample (rectally acquired from the kitten) was wrapped in gauze and suspended in the top of the 60mL syringe in warm tap water. I left it overnight then used a 10mL syringe to suction off the excess fluid, then attached an 18-gauge needle to sample the fluid in the syringe tip. It was very simple to see the larvae under low magnification just with a coverslip over the slide. ♦



General

THE UNFORESEEN ANIMAL WELFARE IMPACTS ASSOCIATED WITH BUSHFIRES

Andrea Harvey

Woodgreen, Wombeyan Caves Area, Via Taralga NSW 2580

C&T No. 5916



Dr Andrea Harvey, feline specialist, animal welfare veterinarian and wild horse researcher tells of her experiences when the Green Wattle Creek Fire hit her home and animal sanctuaries at Wombeyan Caves. How were all the animals kept safe? What unforeseen animal welfare impacts arose? And importantly, what can we do as a profession to try and prevent these unforeseen animal welfare impacts arising in future bushfire events? The aim of this article is to share Andrea's experiences in caring for animals during a bushfire, and to raise awareness of the potential of unpredictable animal welfare impacts, with the hope that more can be done to prevent these issues occurring in the future. Andrea further discusses how although much focus on animal welfare is given to the direct impacts of bushfires, the aftermath of fires and proceeding natural disasters may have similar or even worst impacts that could be better managed.

♦



Read this article in the eBook emailed to all CVE members.

SPECIALISTS' CORNER



Edwina Wilkes

Senior Lecturer and Registered Specialist in Equine Medicine

What attracted you to this discipline?

Horses have been an important part of my life. I was lucky enough to own my first pony when I was 12 years old and it was really just a natural progression for me to study veterinary science. My year as an intern at Agnes Banks Equine Clinic and my time as a registrar at Charles Sturt University cemented my passion for neonatal intensive care and equine critical care so I pursued specialist training in equine medicine.

Worst veterinary experience?

I admitted a horse one weekend which began demonstrating signs of acute neurological dysfunction and deteriorated rapidly. The horse was unvaccinated and exclusion of Hendra virus was very important. It was a very difficult situation from a client communication perspective and the disrespect that equine vets are often shown by owners in these situations is appalling. Social media attention about cases can also be very distressing.

Best veterinary experience?

Working with sick neonatal foals can be very rewarding. I spent 6 months in Kentucky USA (the horse capital of the world) as an equine internal medicine fellow at Hagyard Equine Medical Institute and I loved it. Collecting a pre-race blood sample from Winx, Australia's best racehorse, is also one of my best veterinary experiences!

If you weren't a vet, what would you be?

I have always had an interest in pharmacology which led me to pursue a Master of Pharmacy at the University of Sydney in 2010. I have also considered the option of a job with a dog walking business—what a wonderful way to spend the day, walking dogs in the sunshine! (Continued)

ADVERTISEMENT

K-VET 80mg Tablets, 30mg/mL Liquid

- a more practical and affordable approach to dealing with 2nd generation rodenticides.

K-VET 30mg/mL
Vitamin K1 - 30mg/mL
Palatable Liquid for Dogs and Cats

★★★★★
AVAILABLE EXCLUSIVELY FROM LYPPARD
★★★★★

K-VET LIQUID

- Practical dose volume
- Higher concentration per dose
- Up to 30% less cost than competitors
- Easy to use dosage chart

K-VET 80mg Tablets
Palatable Vitamin K1 Tablets for Dogs and Cats
Key Ingredient: Vitamin K1 (Phytomenadione) 80mg per double scored Tablet
42 TABLETS

K-VET TABLETS

- Accurate dosing with 1/4 scored tablets
- Higher concentration of Vitamin K1 per tablet
- Up to 30% less cost than competitors
- Blister packed for easy dispensing
- Easy to use dosage chart

For more information call 1800 KELATO or 0407 337 499

Kelato ANIMAL HEALTH

Perspective No. 152

MANAGEMENT OF BURNS IN HORSES

EXPERIENCES DURING THE 2019-20 AUSTRALIAN BUSHFIRE CRISIS

Edwina Wilkes BVSc MPharm DVStud FANZCVS

Senior Lecturer and Registered Specialist in Equine Medicine
Charles Sturt University

edwina.j.wilkes@gmail.com

The 2019-20 Australian bushfire season was extraordinary in many ways. More than 18 million hectares of land were burned, at least 3500 homes were lost, and 34 people lost their lives. It was estimated that up to 3 billion animals were killed and the loss of habitat has had a significant impact during the recovery period.

The literature regarding the management of equine thermal injuries is predominantly based on injuries sustained during barn fires, with little information available about the types of injuries and the management of injuries sustained during bushfires.^{1,2} There are some important differences between the impact and types of injuries sustained in barn fires compared to bushfires. In grass fires and bushfires, burns are usually located on the extremities and ventral abdomen, whereas in barn fires, dorsal thermal injuries are more common.¹ Thermal injuries may also result from contact with hot solutions, electrocution or lightning strike, friction (e.g., rope burns), abrasions and chemicals.

A total of 6 horses were hospitalised at the Veterinary Clinical Centre (VCC), Charles Sturt University from January-March for treatment of thermal injuries sustained during bushfires in regions surrounding Wagga Wagga.

Initial Patient Assessment

All horses had 1st, 2nd and 3rd degree burns with the pattern of burn injuries similar among the horses. They were predominantly localised to the face, forelimbs, axilla, ventral abdomen, rump, perineum, hindlimbs and udder region. One mare had severe burns involving the coronary bands of

all four feet and the most severely affected mare had burns involving >25% total body surface area.

Thorough patient assessment is important prior to the instigation of treatment of thermal injuries with particular attention paid to cardiovascular function, pulmonary status, ocular lesions and the extent and severity of the burns.³

The extent of the burn depends on the size of the area exposed, whereas the severity relates to the maximum temperature the tissue attains and the duration of overheating.³ The percentage total body surface area affected usually correlates with mortality, whereas the depth determines morbidity.³

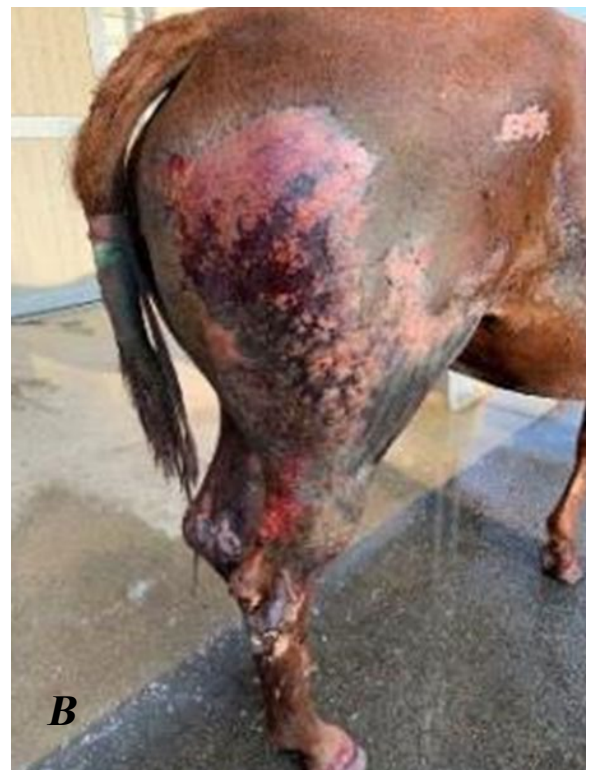
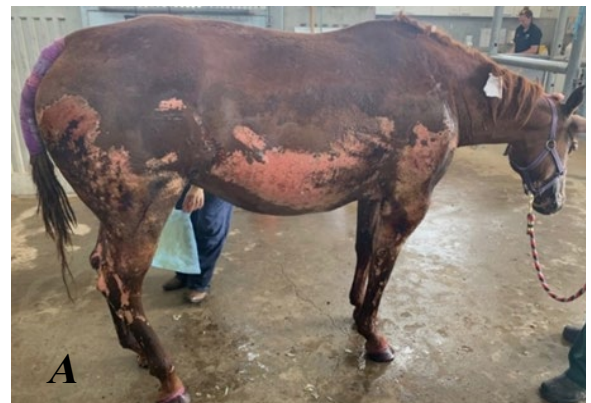
Figure 1 A & B: The most severely affected case, a 9yo QH mare, had burns involving 25% total body surface area.

There are a number of physical criteria used to evaluate burns and these include erythema, oedema and pain; blister formation; eschar (slough produced by a thermal burn) formation; presence of infection; body temperature and cardiovascular

status.³ Erythema, oedema, and pain indicate the presence of some viable tissue and are therefore favourable signs. However, pain is not a reliable indicator for determining wound depth. An accurate evaluation of the severity of a burn often cannot be made until a certain period of time has elapsed to allow further tissue changes.³

Erythema, pain, vesicles, and singed hair are present depending on the extent of the injury and were present in all cases presented to the VCC. It is important to identify injury to major vessels of the lower limbs and the presence of eye, perineal and synovial structure involvement. Signs of ocular/corneal damage may also be present and include blepharospasm, excessive lacrimation or both.³ One mare treated at the VCC sustained severe burns to the left side of her face and a small area of superficial corneal ulceration was detected on ophthalmic examination. The presence of a cough may indicate smoke inhalation, and this was not noted in the horses presented to the VCC. This is often a predominant feature of thermal injuries sustained in barn fires due to exposure to a large accumulation of smoke in a confined/closed space.

The majority of the horses presented to the VCC had mild tachycardia and a fever on initial

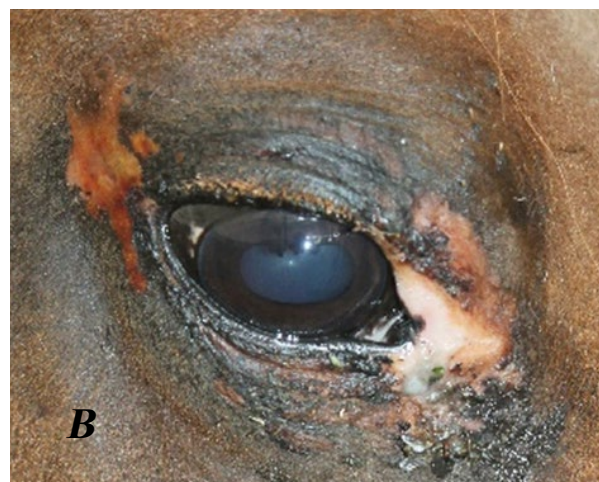
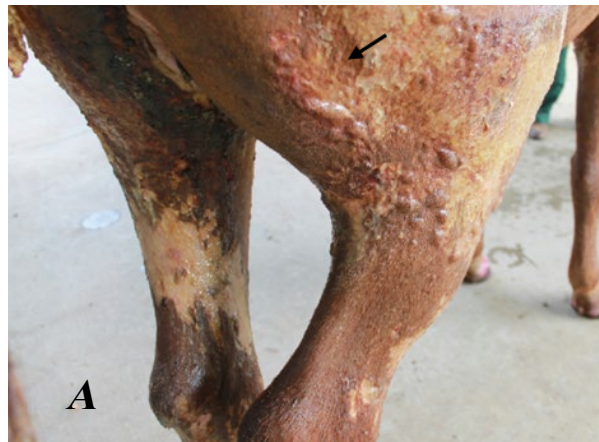

Figure 2 (A) Blister formation (arrow) was common in all cases presented to the VCC. (B) Their eyelashes were also singed, however only one filly presented with corneal damage.

presentation, consistent with the presence of a systemic response to the thermal injuries. Haematological and biochemical examination is useful to assess the systemic response and to identify the presence of organ dysfunction which may develop as a consequence of systemic inflammation, generalised hypoxia and/or severe cardiovascular and haemodynamic compromise. Abnormalities reported in horses with thermal injuries include low total protein concentration and anaemia that may be marked and gradually progressive. This is initially caused by immediate red blood cell (RBC) destruction by heat and wound haemorrhage with subsequent RBC loss from intravascular and extravascular removal of damaged cells.³ Haemoglobinuria can also develop, and this was a feature in one of the cases presented to the VCC. Platelet aggregation on damaged capillary endothelium can result in thrombocytopaenia.³

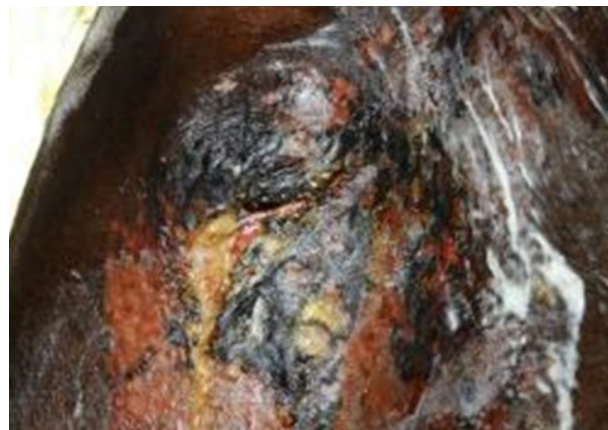

Figure 3. One case, a 3yo QH filly, had severe burns to the left side of her face and a superficial corneal ulcer was detected on ophthalmic examination.

Haematological and biochemical examination in the cases that presented to the VCC revealed changes consistent with a systemic inflammatory response, anaemia and there was also a marked increase in ALP concentration in all horses. This normalised over 3-4 weeks. ALP is present in intestinal mucosa, bile, bone, and renal tubule cells. The hepatic response to thermal injury is well recognised in humans and causes a profound hypermetabolic and hypercatabolic stress response, characterised by increased endogenous glucose production.⁴ As the liver is the primary organ involved in these metabolic responses, changes in liver function can occur within the first 2 weeks of a thermal injury.⁴ In the absence of any other changes suggestive of hepatic or renal disease in the cases presented to the VCC, we assumed the increased concentration of ALP was likely intestinal in origin, as a result of severe systemic inflammation.

Other diagnostic tests which can be considered in cases of thermal injury include a clotting profile, urinalysis, arterial blood gas analysis, thoracic radiography and bronchoalveolar lavage (BAL).

Classification of Burn Injuries

Burns are classified by the depth of the injury with 1st degree burns involving the most superficial layers of epidermis. These burns may be painful but usually heal quickly without complication. They are characterised by erythema, oedema and desquamation of the superficial layers of the skin.³

2nd degree burns may be superficial (basal layers remain relatively uninjured) or deep (all layers of the epidermis). With superficial 2nd degree burns, tactile and pain receptors remain intact and they heal rapidly with minimal scarring in 14–17 days.³ With deep 2nd degree burns, there is necrosis of the epidermis, eschar formation and minimal pain. If further dermal ischaemia is prevented, they may heal in 3–4 weeks, however extensive scarring may occur.³

3rd degree burns involve loss of epidermal and dermal components and are accompanied by extensive fluid loss, lack of pain and eschar formation. Infection of wounds is also a possibility which can result in bacteraemia.³

4th degree burns involve all skin and underlying muscle, bone, ligaments, fat and fascia.³

Pathophysiology of Burn Injury and Initial Patient Stabilisation

Severe burns can lead to dramatic cardiovascular effects, and this is often termed 'burn shock'. This resembles hypovolaemic shock³ and similar effects are seen in humans with extensive burns. A combination of vascular responses ultimately results in an accumulation of fluid, protein, and inflammatory cells in the wound. Tissue ischaemia can continue for 24–48 hours after the initial injury.³ There is also fluid loss into the extravascular space which leads to an acute reduction in blood volume.³ The extent of fluid loss is determined by the severity of the burn and fluid losses will result in increased heat loss from evaporation and an increased metabolic rate.³ This hypermetabolic state results in weight loss and delays wound healing and hence, the condition of the patient prior to injury will play an important role in the prognosis and recovery of the patient.

Protein loss from the vascular space is an important feature of burn injury. With moderate burns, up to 2 times the total plasma albumin pool can be lost from the vascular compartment and the total protein concentration subsequently

decreases significantly.³ Concentrations as low as 30g/L can be expected and this is sufficient to cause substantial fluid shifts and oedema which may be recognised within 60 minutes of the original injury.³ Electrolyte disturbances will accompany fluid and protein shifts in burn injury and should be monitored closely during treatment.

Initial patient stabilisation involves fluid support for the acute haemodynamic alterations that can occur in these cases as well as immediate cooling to halt the burn process.² Intravenous fluid therapy with polyionic crystalloid fluids was instigated in all horses presented to the VCC. Fluid resuscitation is important in avoiding sequelae of haemodynamic shock including decreased gastrointestinal and renal perfusion. Cold water hosing of wounds was also performed at the time of admission, although as these horses presented days after the initial injury, the opportunity to halt the burn process had been missed. Other therapeutic goals during the acute period of burn shock include the administration of anti-inflammatory agents and all patients admitted to the VCC were initially treated with flunixin meglumine. This also formed part of a more comprehensive pain management plan which is outlined below. Environmental management was also important, and the use of misters and fans helped to keep the horses cool despite the very high ambient temperatures.

Wound management

Wound management was a major component of the daily management of the cases presented to the VCC. Essentially, the local care of burns generally involves halting the burning process, cleansing and debridement and application of topical ointments and/or dressings to support healing. Initial cooling of the surface of the burn is important for alleviating pain and ending progression of tissue necrosis caused by elevated temperatures.⁵

The wounds were hosed, gently cleansed, and dressed twice daily and this sometimes took up to 2–3 hours to attend to the wounds on all the horses. The use of cold water (2–15°C) treatment as first aid for burns has the greatest volume of supporting literature, compared to using ice which may lead to a thicker eschar and may worsen ischaemic necrosis.⁵ Cold water stops the burning process by cooling the tissue and preventing progressive necrosis of cells and it can also dampen the inflammatory response.⁵ Mild natural soap (Sunlight® soap) was used to facilitate softening and removal of dead skin and was generally well tolerated, although some horses required sedation for wound management. Dilute chlorhexidine and betadine/iodine were avoided in these cases due to the concern of causing skin irritation.

Burns are prone to infection due to the loss of the physical barrier to infection and the warm, moist site of the wound is an ideal environment for bacteria to multiply.⁶ Human burns patients are particularly vulnerable to infections with over 75% of all burn deaths a result of infection.⁷ There are multiple topical antiseptic and antibacterial creams available for use in horses. Silver sulfadiazine (SSD) cream, a broad-spectrum antibacterial 1% water miscible cream, was used on the majority of the burns in these cases. Although SSD has led to a significant reduction in the incidence of burn wound sepsis in humans, there is increasing evidence of the potential for severe side effects (including hepatic or renal toxicity and leukopenia) and recent reports also describe the formation of a pseudoeschar layer on the burn wound after the use of SSD which may preclude wound evaluation.⁶ A cytotoxic effect has also been demonstrated on epidermal cells with hair follicle death resulting in a delayed healing rate.⁷ However, SSD is still recommended if treatment with the newer advanced antimicrobial and biosynthetic dressings, now available for humans, is not a practical option and it is very commonly used in equine practice with very good results. There have been few systemic side effects reported in horses.³

Honey provides a moist healing environment while successfully preventing bacterial growth and does not have the side effects of antibiotics.⁶ Its antibacterial properties and viscosity effectively provide a barrier to cross-infection of wounds and it has been used in the treatment of burns in humans.⁶ Honey was also used in the cases presented to the VCC and in our experience, there was less exudation and erythema compared to burns treated with SSD cream. However, on exposed, unbandaged areas, the honey dried quickly and attracted insects (flies, ants etc.). These experiences were similar to those reported

Figure 4: The cleaning and dressing of the wounds took many hours each day and we were extremely grateful for the help of many CSU staff and student volunteers during this time.



by Herbert *et al.*¹ in their management of horses injured in bushfires in the Pinery region of South Australia in November 2015. We therefore used a combination of SSD cream and honey in the cases presented to the VCC and both were well tolerated.

Bandaging is the standard of care in the management of burns in human patients and in the cases presented to the VCC, the wounds on the distal limbs were initially bandaged with multi-layer bandages. However, this was not well tolerated in the hot weather and the horses were also quite pruritic and continually scratched their distal limbs, causing the bandages to slip. The use of single layer compression bandages, impregnated with silver (for its antimicrobial properties) was much better tolerated and they also helped to reduce the distal limb oedema and amount of exudation from the wounds.

The use of systemic antimicrobials is not warranted in the treatment of burn injuries in horses as they do not favourably influence wound healing, fever, or mortality. They are unable to penetrate the avascular eschar where the risk of contamination is greatest.³ The circulation to the burned area is often compromised, making it highly unlikely that parenteral administration of antimicrobials will achieve therapeutic levels at the wound. Their use may also encourage the emergence of resistant microorganisms. The use of topical antimicrobials can successfully prevent the extension of superficial wound infection to systemic sepsis.³

Wound Progression

As heat is slow to dissipate from burn wounds, it is often difficult to evaluate the severity of tissue damage accurately in the early phase of injury. Time must elapse to allow further tissue changes and allow accurate evaluation of burn severity. It was a case of 'the worst was yet to come' in all of the cases treated at the VCC.

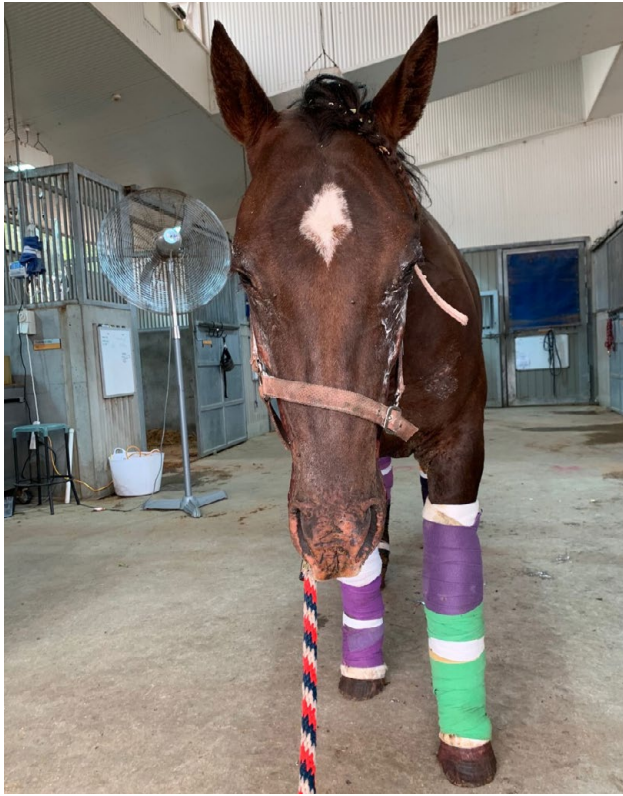

Figure 5: Multi-layer bandages were initially placed on the distal limbs; however, these were not well tolerated by the horses.

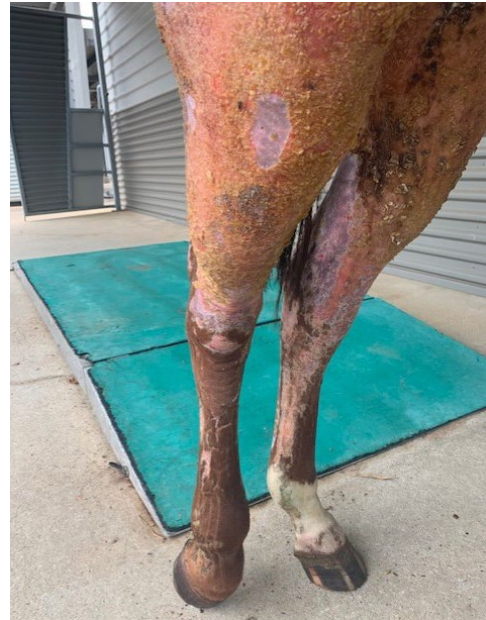


Figure 7: When the compression wraps were removed each morning, there was evidence of less exudation from the wounds as shown on the medial aspect of the left hindlimb in this photograph. They also helped to decrease the distal limb oedema.

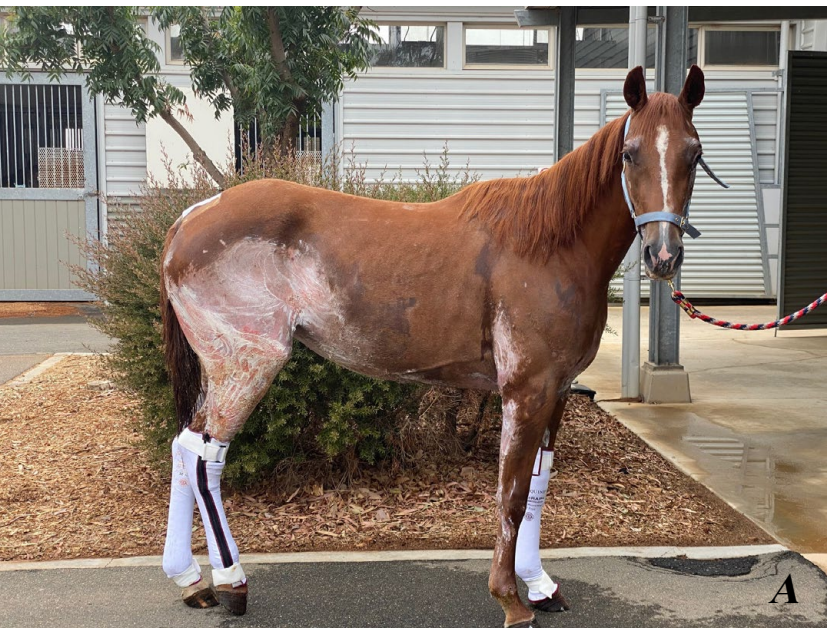

Figure 6 (A&B): We were overwhelmed with very generous donations including these silver impregnated compression wraps (Sol Equine®) which were very well tolerated by the horses.


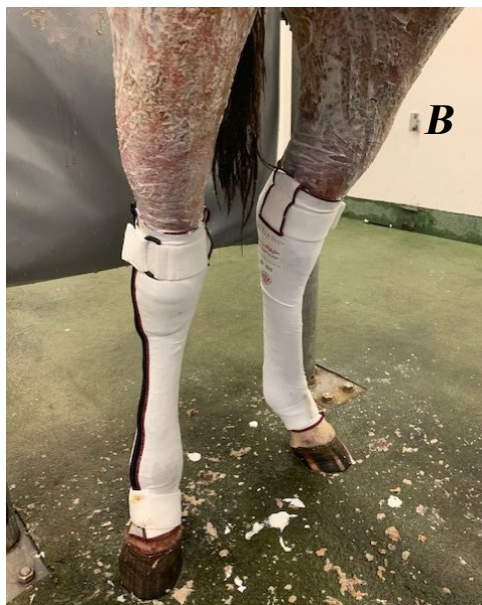


Figure 8: In the days immediately following admission to hospital, the skin in the affected areas became very firm and 'leathery' prior to eventually sloughing.

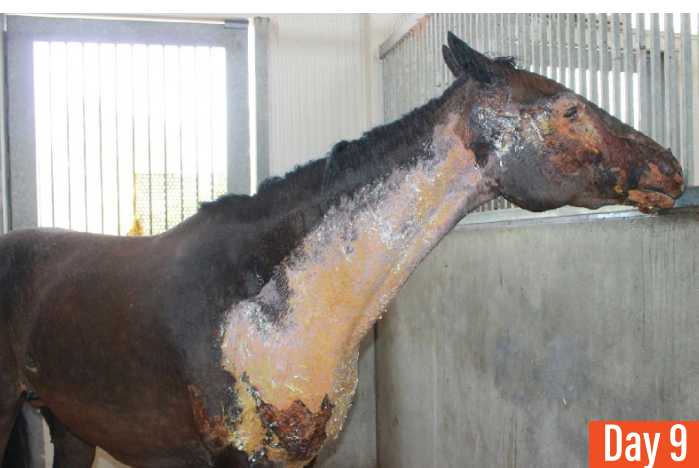
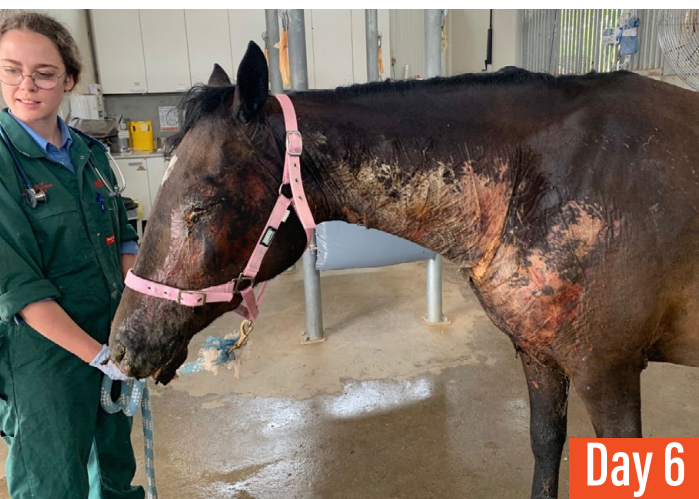
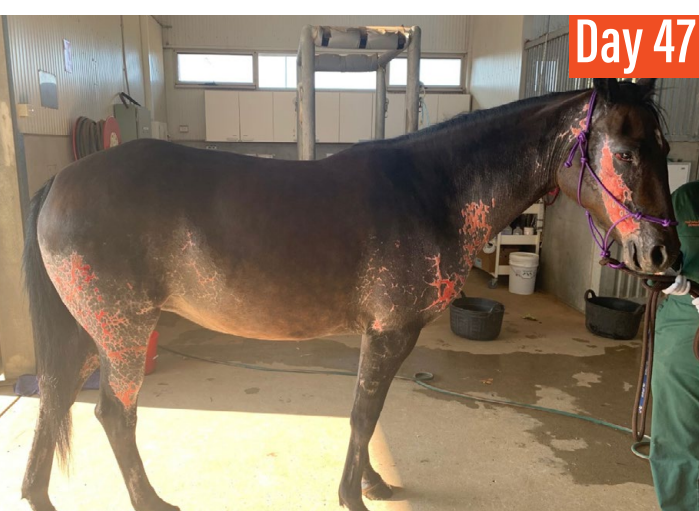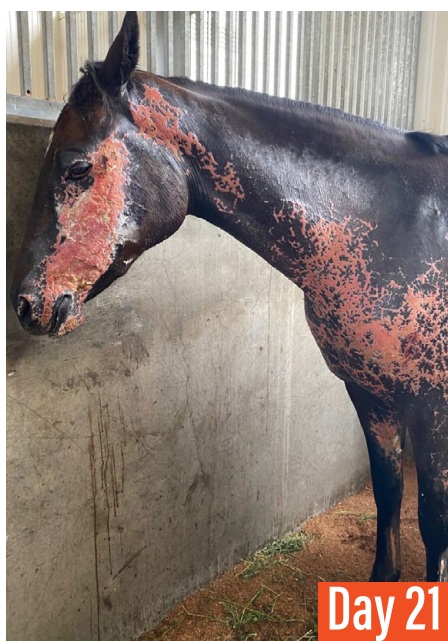Figure 9 (Day 6, 9, 21 & 47): Series of photographs showing the progression of the wounds the 3yo Quarter Horse filly. This filly had severe 3rd degree burns on the left side of her face and neck.



Burns heal very slowly and many weeks are often required for the wound to close by means of granulation, contraction and epithelialisation.³ In some cases, skin grafting following eschar removal may be considered, particularly in deep partial-thickness wounds which can have high rates of bacterial contamination. Skin grafting was not required in any of the cases presented to the VCC. Second-intention healing results in a thin and hairless epithelium that is vulnerable to trauma³ and this was an important consideration in the future management of the cases and their ability to return to athletic function.

Treatment Challenges

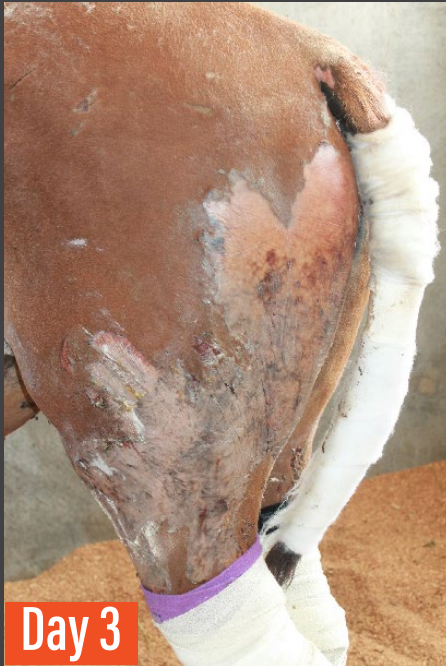A number of challenges were faced while treating these horses and although certain aspects of the treatment and management were consistent between cases, the treatment regimen was tailored to each individual case.

(i) Pain management

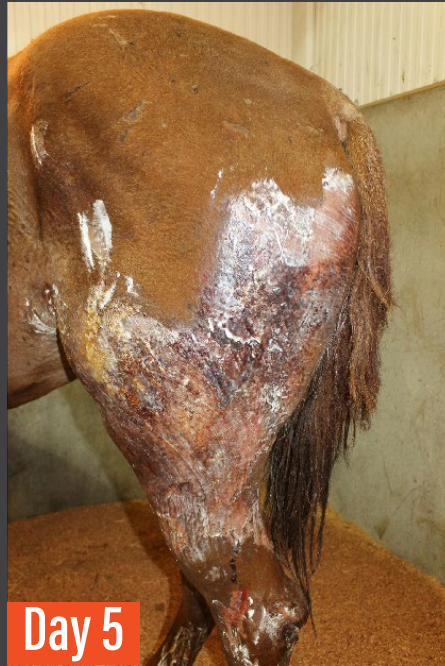Pain management was a primary component of the treatment regimen in each case. With severe tissue injury (as occurs with thermal injuries), physiologic pain can evolve to state of pathologic pain if not appropriately managed. Multimodal pain control was considered to be most appropriate for these cases as it has the advantage of additive or synergistic analgesic effects, and it also allows the use of lower doses of individual analgesic agents to limit the negative side effects. The aim of multimodal pain control is to decrease the nociceptive input into the CNS and the development of central sensitisation and ultimately prevent or limit the development of concurrent chronic pain.⁸

The development of neuropathic pain was also a concern in these cases. It occurs after injury to peripheral or CNS neurons and is associated with ongoing pain, hyperalgesia, and allodynia, typically poorly responsive to conventional analgesics.

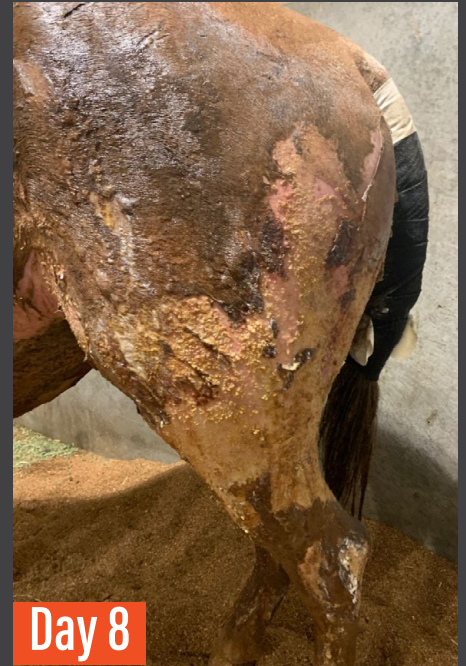As well as twice daily administration of NSAIDs, constant rate infusions (CRI) of lidocaine, ketamine and morphine were used in the initial period of hospitalisation with very good response. In some cases, an α_2 agonist (detomidine) and anxiolytic (acepromazine) were added to the CRI to aid in the management of agitation and pruritis. There is a risk of decreased gastrointestinal motility with the use of α_2 agonists and opioids, however pain and inflammation can also negatively impact motility and hence, the potential for the development of ileus should not override the need to provide adequate analgesia. The delivery of these drugs via CRI may mitigate some of these unwanted side effects.



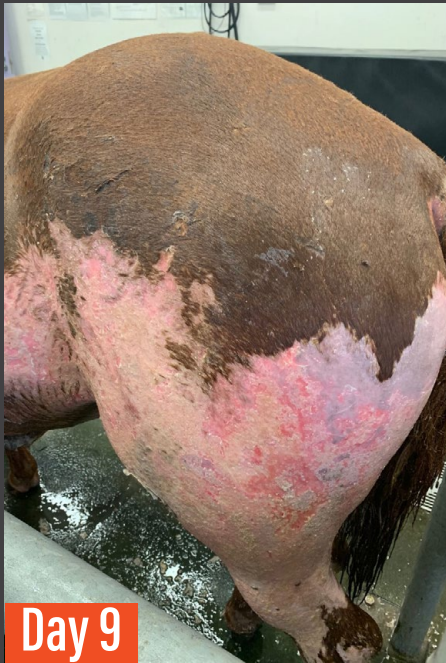Day 3



Day 5

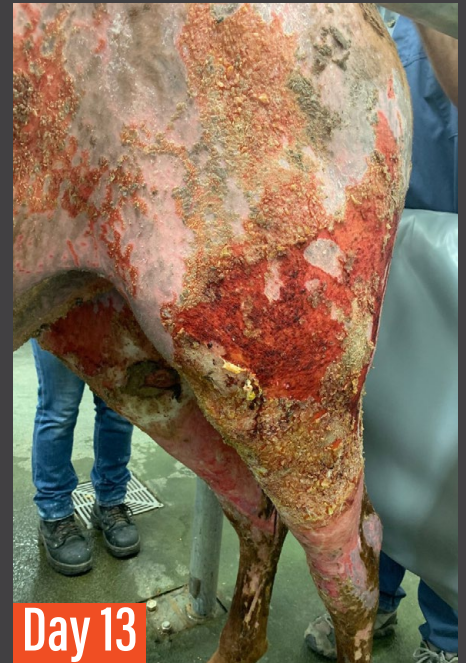

Day 8

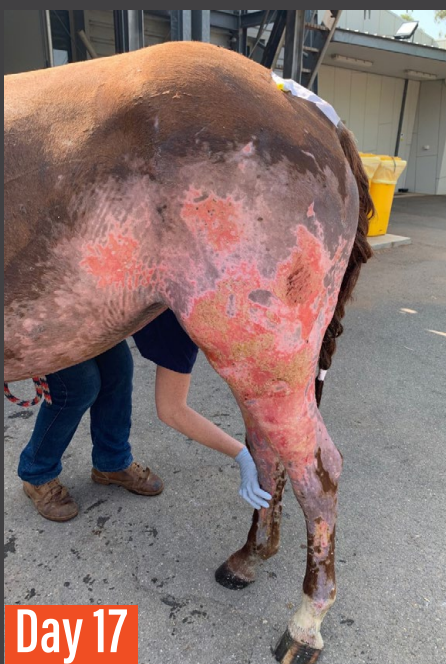

Day 9

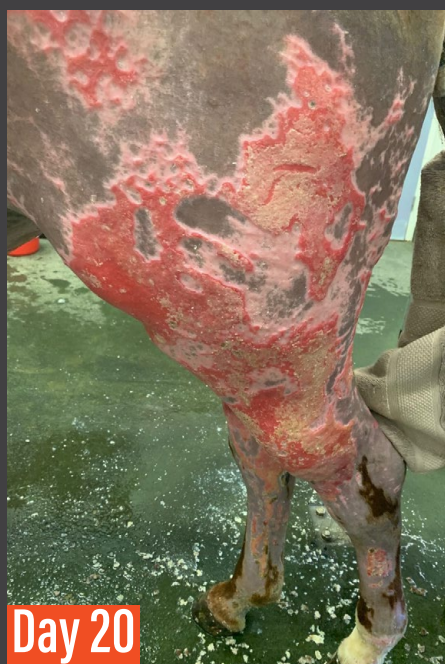Figure 10: Series of photographs showing the progression of the wounds in the 1yo QH filly. This filly had severe third degree burns to her ventral abdomen, rump, perineum, hindlimbs and udder region.



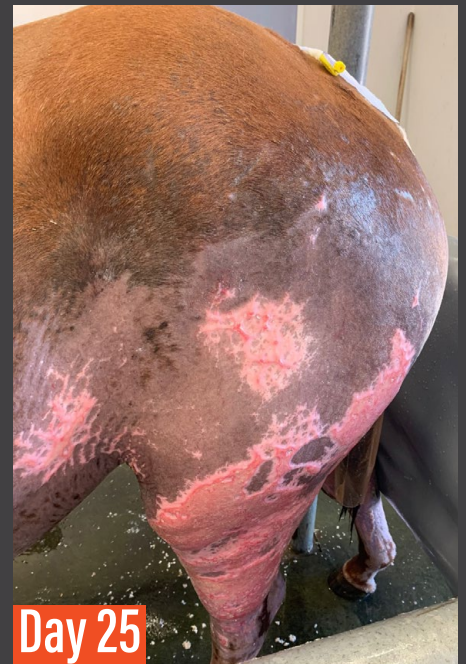Day 13



Day 17



Day 20



Day 25

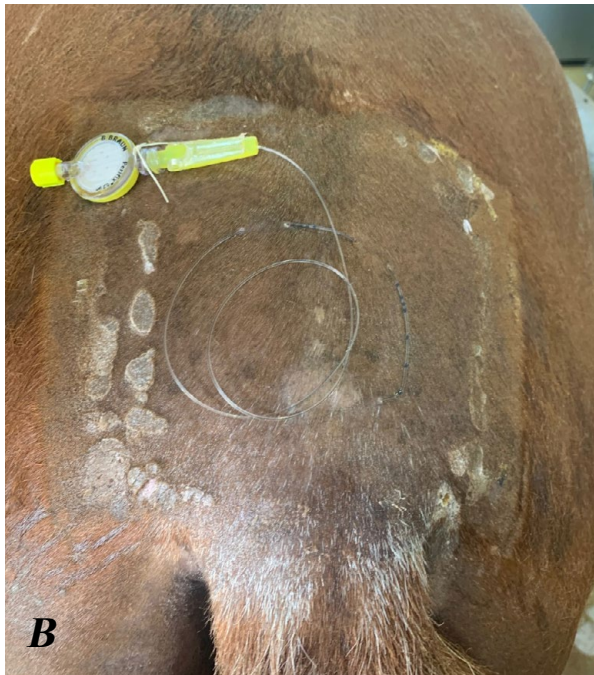
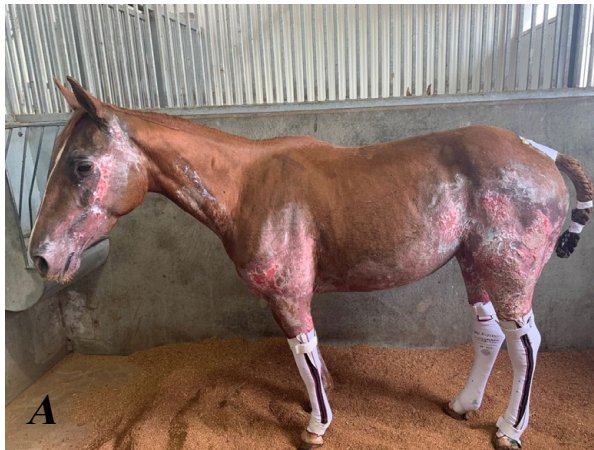

Figure 11: (A) Yearling QH filly with severe burns involving her hindlimbs, perineum and udder region. (B) There is an indwelling epidural catheter in place which provided very effective pain control.

Treatment with gabapentin and paracetamol was also continued throughout hospitalisation. Gabapentin is an anticonvulsant but is also used in pain management (particularly neuropathic pain) in humans. Gabapentin and paracetamol are often used in the management of pain associated with chronic laminitis in horses and although there is limited current evidence to support their use, there are anecdotal reports of successful management of pain with no apparent adverse effects following oral administration in horses.

In one case (yearling QH filly), there were severe burns on the hindlimbs and in the perineal and udder regions. She became intolerant of daily wound cleaning despite heavy sedation. A decision was made to place an indwelling epidural catheter which was in place for 3 weeks with no associated complications. Epidural administration can provide analgesic effects with significantly decreased systemic adverse effects in horses with severely painful hindlimb conditions.⁹

A combination of an α_2 -agonist (detomidine) and an opioid (morphine) was administered once daily prior to cleaning and dressing the wounds. The response was excellent with marked improvement in her tolerance of wound cleaning/dressing and her demeanour also noticeably improved.

(ii) Pruritis

Pruritis is a common symptom affecting the majority of human burns patients and this was also noted in the cases we treated. Some of the horses were severely pruritic, resulting in extensive self-trauma, through rubbing, biting, and pawing. The episodes of pruritis are often most intense in the first weeks after a burn injury during the inflammatory phase of repair and when the eschar is sloughing.³

Pruritic stimuli are transmitted by a subpopulation of C-fibres extending from the skin to the dorsal root ganglion of the spinal cord. The impulses are then conveyed onto higher CNS centres to the cortical areas.¹⁰ The two parts of the pruritic pathway (peripheral and central), form different targets for pharmacological intervention.¹⁰

Oral antihistamines are commonly used to manage pruritis in humans, however these are less effective in horses and were not used in the cases presented to the VCC. Gabapentin is used as a centrally acting agent and may prevent the sensitisation of neuronal pathways and the development of refractory pruritis. Although gabapentin was primarily prescribed for pain management in the cases presented to the VCC, it was evident that it also effectively managed the pruritis as when we initially attempted to taper the dose, the pruritis became worse in a number of cases.

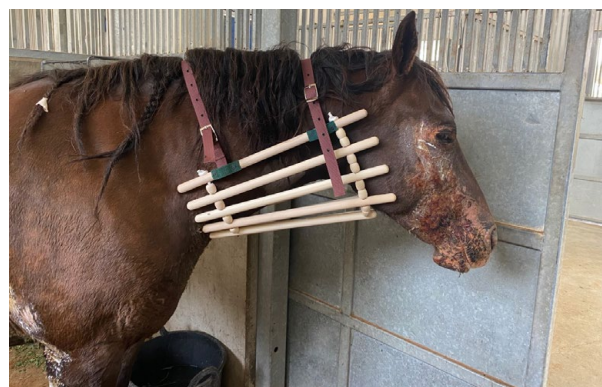

Figure 12: Collars were used in the management of pruritis

Pruritis was also managed with an anxiolytic (acepromazine) initially and there was mild improvement. Reserpine, an indole alkaloid used for long term tranquilisation in horses was also used and there was very good response to this



Figure 13 (A&B): Made to measure Hidez® compression suits were generously donated by the company. These suits provide compression and can improve comfort and circulation with these types of injuries. They also helped to alleviate the pruritis.

treatment. Reserpine blocks the transport of monoamine neurotransmitters to the synaptic cleft¹¹ and has been found to decrease the urge to scratch.

Second line adjunct therapy in humans includes laser and pressure garment therapy. Body compression suits made by Hidez® were generously donated by the company for use in the cases presented to the VCC. We used these towards the end of the period of hospitalisation when the wounds were slightly less exudative. They were well tolerated and have also been found to improve comfort and circulation.

(iii) Nutritional management

There is a significant increase in metabolic rate in patients with burn injuries and this will result in increased body temperature, oxygen consumption, fat degradation and protein and glucose use.³ The caloric expenditure and protein catabolism are very high and often considerably higher than in other states of physiological stress.³ Therefore, appropriate nutrition and caloric and protein supplementation is an important consideration in the treatment of these cases.

Nutritional support is recognised as one of the most important components of the management

of human patients with severe burn injuries as a result of the marked hypermetabolic response that occurs.⁴ This was an important consideration in the cases presented to the VCC as although the horses were in good body condition at the time of presentation, their injuries were severe enough to cause marked protein loss and ongoing protein catabolism in the weeks following the initial injury. In order to avoid rapid depletion of skeletal muscle, delayed wound healing and impaired cellular defence mechanisms, it was important to adjust the caloric and protein intakes to maintain bodyweight.

Nutritional support can include enteral and parenteral routes. Early enteral feeding decreases weight loss and maintains intestinal barrier function which reduces bacterial translocation and subsequent sepsis.³ In the most severely affected case, an indwelling enteral feeding tube was placed to facilitate administration of a high calorie supplement (Jevity®) which is frequently used in the management of human burns patients.

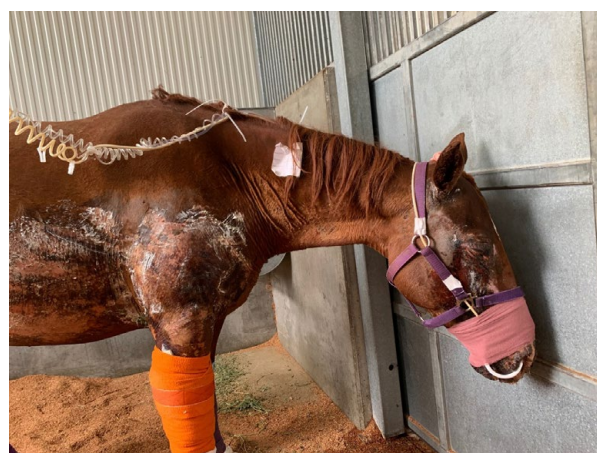


Figure 14: An indwelling nasogastric tube was placed in the most severely affected case, a 9yo QH mare. This allowed enteral feeding with a high calorie supplement.

We received generous donations of high-quality Lucerne hay and a feed company (Coprice®) donated a selection of pelleted feeds that were high in protein and fat. Grain was gradually introduced into the horses' diets and fat was also added in the form of vegetable oil. They were offered free-choice Lucerne hay throughout hospitalisation.

(iv) Laminitis

Three of the cases presented to the VCC had severe burns around the coronary bands of all four feet and there was concern that this may ultimately result in a decrease in blood supply to the sensitive digital laminae. Close monitoring of digital pulses was continued throughout hospitalisation as well as serial radiography to monitor for any evidence of pedal bone rotation.

One mare developed severe laminitis in her right fore and proposed mechanisms for the development of laminitis in this case included inflammatory (from severe tissue injury involving the distal limbs and systemic inflammation) and insulin dysregulation. In human burns patients, insulin resistance is a common sequelae of thermal injury and the reduction of acute post-traumatic hyperglycaemia is a key element in decreasing mortality and morbidity in these patients.¹² While this has not been directly investigated in equine patients, the mare with severe laminitis had many phenotypic characteristics of Equine Metabolic Syndrome and therefore, insulin dysregulation may have played a role in the development of laminitis. The measurement of insulin concentrations throughout hospitalisation and the use of metformin for the management of post-prandial hyperinsulinaemia may be warranted in cases of severe thermal injury.

Digital cryotherapy was attempted for the management of laminitis in this case; however,

this was complicated by the presence of severe burns on the palmar/plantar aspect of the distal limbs and pastern. Cryotherapy caused extensive maceration of these wounds and had to be discontinued. Solar support was provided with the use of Soft Ride® Boots and the stable was deeply bedded. Unfortunately, there was progression of the laminitis and ultimately solar penetration in the right fore. The mare was subjected to humane euthanasia.

(v) Wound contracture and skin fragility

As the wounds healed, there was often marked contraction of the skin and in one case, there was contracture around the lower eyelid on the left side and subsequent ectropion. There was concern for the development of exposure keratitis and predisposition to corneal ulceration. 6 months after her initial presentation, the mare re-presented for corrective surgery and a V to Y plasty procedure was performed. There has been ongoing gradual improvement as the healing has progressed.

Deep partial thickness wounds require several months to heal and second-intention healing results in thin and hairless epithelium that is vulnerable to trauma.³ We faced challenges associated with a general lack of skin compliance which in some cases, resulted in splitting of the skin in multiple areas. Daily application of paraffin-based emollients (e.g., Sorbolene® cream) and Vitamin E was helpful in the management of affected areas. It needs to be considered that the delayed healing and poor epithelialisation and complications of 2nd intention healing may limit the return of the animal to its previous use. The option for skin grafting was considered in these cases, however the persistent skin splitting precluded the chance of successful grafting.

Hypertrophic scars developed after deep second-degree burns in some of the cases presented to the VCC. These usually remodel in a cosmetic manner without surgery in 1-2 years, however as the scarred skin is hairless and often depigmented, sun exposure must be limited.³ The continued use of the compression suits was also recommended at the time of discharge as an effective method of limiting sun exposure.

Malignancy following burn injuries has been described in humans and the predominant neoplasm that develops is squamous cell carcinoma.¹³ Chronic (latent) malignancy can develop up to 7 years after the initial injury and this is more common than acute malignancy that develops within one year.¹³ Persistent irritation from chronic infection and trauma to the poorly

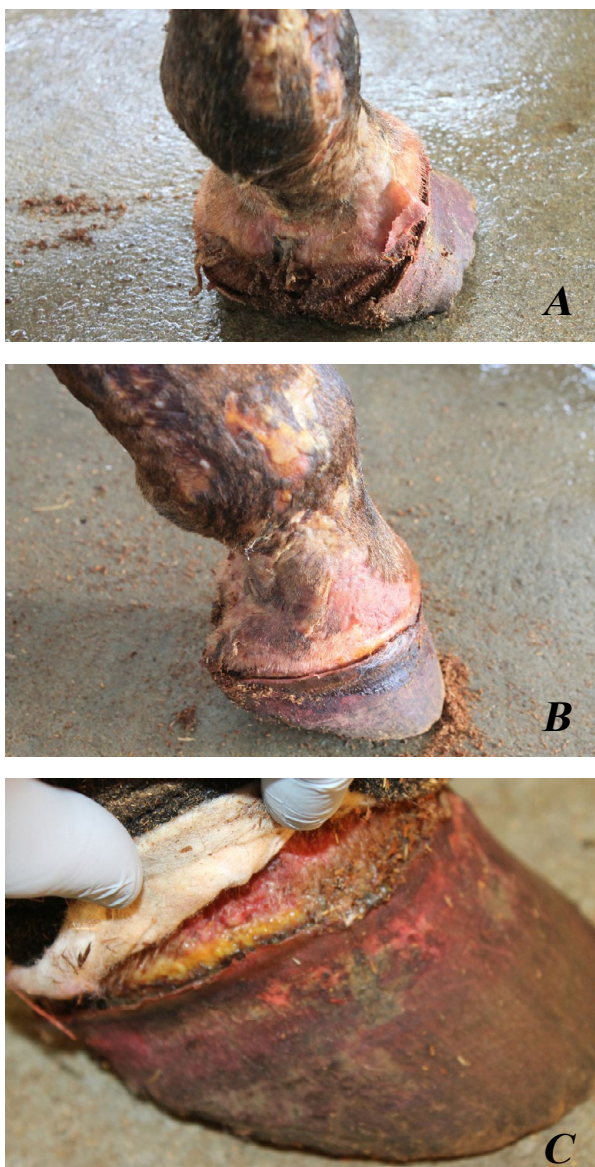


Figure 15 (A,B&C): Photographs showing severe coronary band burns in one of the cases treated at the VCC.

Figure 16 (A&B): The use of digital cryotherapy in the management of the laminitis was complicated by the presence of burns on the palmar/plantar aspect of the distal limbs (A). Solar support was provided through the use of Soft Ride® boots (B).

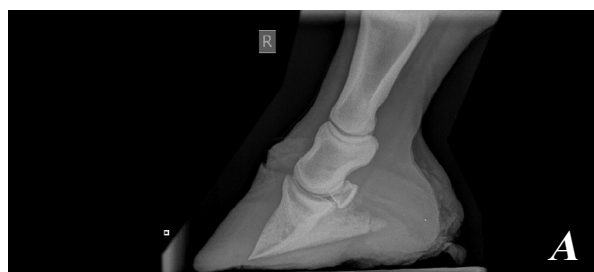
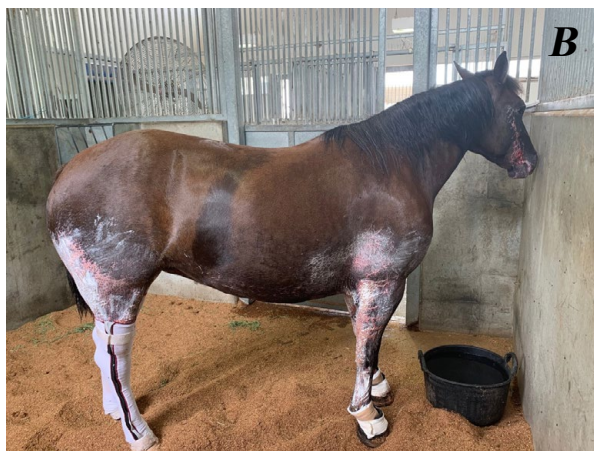
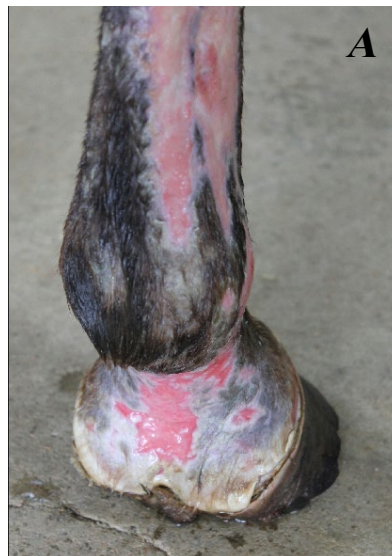Figure 17 (A&B): Marked pedal bone rotation and ultimately solar penetration occurred in one case, a 6yo QH mare.

vascularised burn scar is suggested as the cause of neoplastic change within the scar. After each insult, healing becomes more difficult and the regenerated epithelium becomes increasingly inferior.¹³ Persistent stimulation to marginal epithelium may lead to metaplasia and eventually neoplasia. Burn-induced neoplasia is less likely to develop in a primarily grafted burn¹³ and this is an important consideration when deciding whether grafting is indicated in the management of burn injuries. Neoplasia should be considered as a differential diagnosis when excessive tissue proliferation occurs at the site of a previous burn as early diagnosis and treatment may prevent rapid metastasis.¹³

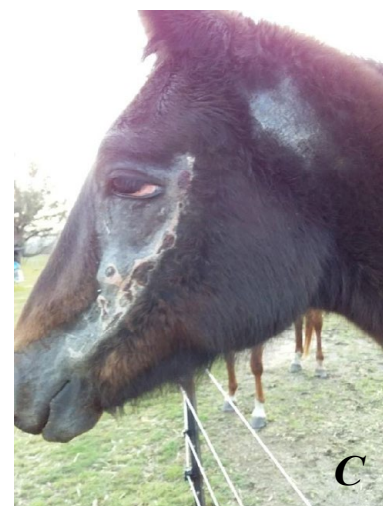
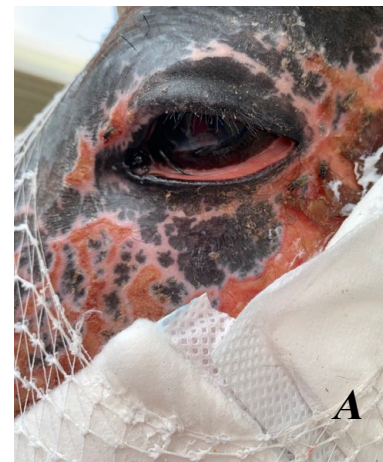


Figure 18 (A,B &C): Photographs demonstrating the wound contracture and ectropion that developed over time as a consequence of deep 3rd degree burns in the 3yo QH filly.

(vi) Colic

The 9yo QH mare who sustained burns to >25% of her body surface area developed severe colic and the management of this was made more complicated by the severity and location of her burns. There were a number of likely risk factors for the development of colic in this case including stress, pain, hospitalisation, change in diet, endotoxaemia (as a sequelae of SIRS). The requirement for intensive analgesia with the use of opioids may have also caused a reduction in gastrointestinal motility. The mare demonstrated persistent abdominal discomfort despite regular administration of analgesia and her abdomen became markedly distended. Exploratory

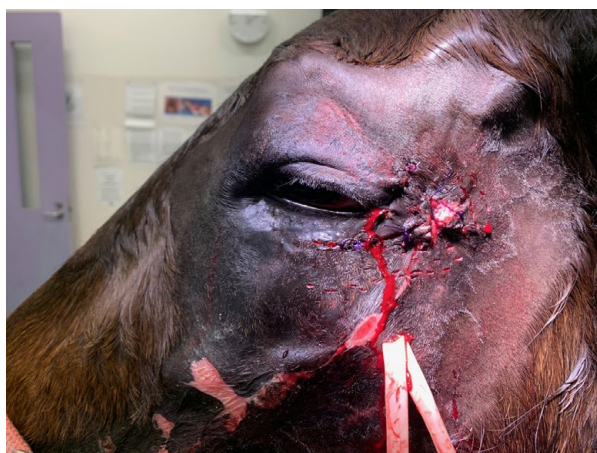

Figure 19: A V-Y plasty procedure was performed 4 months following discharge from the hospital.

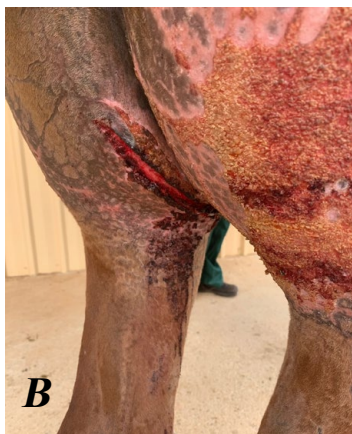
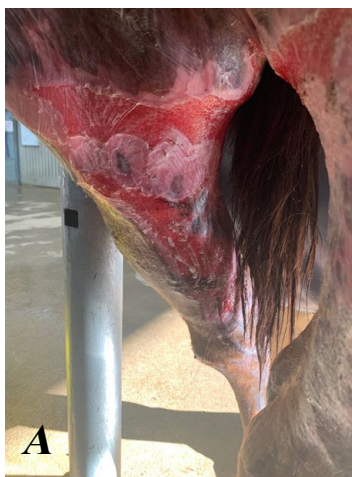
Figure 20 (A&B): As the wounds healed, areas of skin became very fragile and often split in multiple locations.

laparotomy was not considered a viable option in this case due to severe burns in the ventral midline region which would have compromised incision healing. The systemic status of the patient with evidence of haemodynamic compromise as a result of severe fluid and protein loss from the burns was also a major consideration in terms of assessing her anaesthetic risk. Unfortunately, the mare was subjected to euthanasia due to rapid clinical deterioration within the first 5 days of hospitalisation.

Outcome

Four of the horses presented to the VCC were eventually discharged from hospital and continue to progress well at home. **A number of valuable lessons were learned from treating the cases that presented to the VCC.**

- The management of extensive and severe burns is difficult, expensive, and time-consuming and long-term care is usually required to prevent continued trauma to the affected areas.
- It is important to discuss the likelihood that horses may not return to full athletic function when counselling owners on the management of these cases.
- Minor first-degree and superficial second-degree burns can usually successfully be managed in a field setting, however extensive first- and second-degree burns and third- and fourth-degree burns are ideally managed by referral to an intensive care facility.
- The consideration of secondary injuries and close monitoring for complications including laminitis is very important.



Figure 21: Photograph showing the development of hypertrophic scars as a sequelae of deep second-degree burns. The skin in these areas is hairless and depigmented.

Acknowledgements

The management of these cases would not have been possible without the help of many staff and student volunteers at CSU as well as other clinicians and support staff at the Veterinary Clinical Centre. We were overwhelmed by the generosity of the community locally, nationally, and internationally! We had numerous donations of many different products to assist with the management of the cases as well as horse feed, bandaging materials and compression suits.

As we prepare for more hot summers in Australia, it is important that we use these previous experiences to improve our preparedness for the treatment of horses with thermal injuries if we happen to be faced with them again.

Contact me

edwina.j.wilkes@gmail.com.

If you have any questions regarding anything discussed in this article, please do not hesitate to get in touch.

References

1. Herbert EW. Findings and strategies for treating horses injured in open range fires. *Equine Vet Educ* 2018;30:177-186.
2. Marsh PS. Fire and smoke inhalation injury in horses. *Vet Clin North Am Equine Pract* 2007;23:19-30.
3. Hanson RR. Management of burn injuries in the horse. *Vet Clin North Am Equine Pract* 2005;21:105-123.
4. Price C. Nutrition: reducing the hypermetabolic response to thermal injury. *Br J Nurs* 2018;27:661-670.
5. Cuttle L, Pearn J, McMillan JR, et al. A review of first aid treatments for burn injuries. *Burns* 2009;35:768-775.
6. Malik KI, Malik MN, Aslam A. Honey compared with silver sulphadiazine in the treatment of superficial partial-thickness burns. *International Wound Journal* 2010;7:413-417.
7. Norman G, Christie J, Liu Z, et al. Antiseptics for burns. *The Cochrane database of systematic reviews* 2017;7:Cd011821.
8. van Loon JPAM. Multimodal strategies for equine analgesia, one step beyond.... *Equine Vet Educ* 2014;26:72-74.
9. Rønnow Kjærulff LN, Dorch Lauritsen NJ, Thorn Ekstrøm C, et al. Caudal epidural co-administration of methadone and morphine in horses: An evaluation of analgesic properties and effects on locomotor function, mentation and physical examination parameters. *Equine Vet Educ* 2020;33:360-367.
10. Goutos I, Clarke M, Upson C, et al. Review of therapeutic agents for burns pruritus and protocols for management in adult and paediatric patients using the GRADE classification. *Indian journal of plastic surgery : official publication of the Association of Plastic Surgeons of India* 2010;43:S51-S62.
11. Gilbertie JM, Davis JL, Davidson GS, et al. Oral reserpine administration in horses results in low plasma concentrations that alter platelet biology. *Equine Vet J* 2019;51:537-543.
12. Xin-Long C, Zhao-Fan X, Dao-Feng B, et al. Insulin resistance following thermal injury: an animal study. *Burns* 2007;33:480-483.
13. Schumacher J, Watkins JP, Wilson SR, et al. Burn-induced neoplasia in two horses. *Equine Vet J* 1986;18:410-412. ♦



DIRTY WOUNDS? WE HAVE THE SOLUTION!

Wounds can vary widely in how they present, from straight forward through to complex, challenging us at every turn. Wounds may be superficial, gaping full thickness or punctures that go deeper than we can see, but no matter the depth of the wound, if it is not clean it cannot heal.

What is Biofilm?

Biofilm forms when bacteria adhere to surfaces by excreting a thick, glue-like substance known as the Extracellular Polymeric Substance (EPS). This substance forms a protective layer, where the bacteria are no longer free to move (planktonic) but adhere to the wound bed. New bacteria are produced, and the colony grows under the protection of the EPS. Biofilms are often difficult to detect visually, but they delay wound healing due to the protection they provide to the bacteria in the wound bed.³

The Solution

Traditional wound cleansing with saline and water is ineffective at removing coatings and debris in many wounds, especially complex biofilms.⁴ Prontosan® Irrigation Solution and Prontosan® Wound Gel/Gel X are specifically indicated for the prevention and removal of biofilms. Prontosan® contains two key ingredients: Betaine and Polyhexanide.

Betaine is a gentle surfactant which is able to disturb, penetrate, clean and remove biofilm and wound debris.

Polyhexanide (PHMB) is a broad-spectrum antimicrobial with demonstrated good clinical safety, no evidence of resistance and minimal toxicity. It functions as a preservative which inhibits the growth of micro-organisms.^{5,6,7}

The unique combination of Polyhexanide and Betaine have a double effect on the wound bed to create a wound environment optimal for healing.

For more information and to see how it works visit:

How it works?



There is a plastic granulate on the surface.



References

3. Davis SC, Harding A, Gill J, Parajon F, Valdes J, Solis M & Higa A "Effectiveness of polyhexanide irrigation solution on MRSA biofilms in a porcine wound model" *IWL 1742-4801*, 2017, 1-8.
4. Murphy C, et al. International consensus document. Defying hard-to-heal wounds with an early antibiofilm intervention strategy: wound hygiene. *J Wound Care* 2020.
5. Fabry, W. & Kock, In-vitro activity of polyhexanide alone and in combination with antibiotics against *Staphylococcus aureus*. H.-J. *Journal of Hospital Infection*. 2014
6. Hirsch et al., Evaluation of Toxic Side Effects of Clinically Used Skin Antiseptics In Vitro, *Journal of Surgical Research* 2010 202010 Volume 164, Issue 2.
7. Bradbury S, Fletcher J. Prontosan® made easy. www.woundsinternational.com 2011;

ADVERTISEMENT



www.bbraun-vetcare.com.au

Australian VetCare website now available!



Browse items by Therapy Area



Access training and support material 24/7



E-Shop for existing customers